

# Causes of mortality in green turtles from Hawaii and the insular Pacific exclusive of fibropapillomatosis

Thierry M. Work<sup>1,\*</sup>, George H. Balazs<sup>2</sup>, Tammy M. Summers<sup>3</sup>, Jessy R. Hapdei<sup>3</sup>, Alden P. Tagarino<sup>4</sup>

<sup>1</sup>US Geological Survey, National Wildlife Health Center, Honolulu Field Station, PO Box 50167, Honolulu, HI 96850, USA

<sup>2</sup>NOAA National Marine Fisheries Service, Pacific Islands Fisheries Science Center, 1845 Wasp Boulevard, Building 176, Honolulu, HI 96818, USA

<sup>3</sup>Commonwealth of the Northern Marianas Department of Land & Natural Resources, Sea Turtle Program, Saipan, MP 96950, USA

<sup>4</sup>American Samoa Government, Department of Marine & Wildlife Resources, Wildlife Division, PO Box 3730, Pago Pago, AS 96799, USA

**ABSTRACT:** Fibropapillomatosis (FP) comprises a majority of green turtle stranding in Hawaii; however, green turtles in the Pacific are also susceptible to non-FP related causes of death. We present here necropsy findings from 230 free-ranging green turtles originating from Hawaii, the Mariana archipelago, Palmyra Atoll, American Samoa, and Johnston Atoll that died from non-FP related causes. Most turtles died from fishing-induced or boat strike trauma followed by infectious/inflammatory diseases, nutritional problems (mainly cachexia), and an array of physiologic problems. Infectious/inflammatory problems included bacterial diseases of the lungs, eyes, liver or intestines, spirorchid fluke infection, or polyarthritis of unknown origin. Likelihood of a successful diagnosis of cause of death was a function of post-mortem decomposition. Fibropapillomatosis was not seen in turtles submitted from outside Hawaii. The preponderance of anthropogenic causes of mortality offers some management opportunities to mitigate causes of death in these animals by, for example, implementing measures to decrease boating and fishing interactions.

**KEY WORDS:** Green turtle · *Chelonia mydas* · Mortality · Pathology · Trauma · Infectious disease · Nutrition · Pacific

Resale or republication not permitted without written consent of the publisher

## INTRODUCTION

Green turtles *Chelonia mydas* in the Pacific islands from this study are listed as 'Threatened' under the US Endangered Species Act and 'Endangered' under the International Union for Conservation of Nature (IUCN) red list. However, the Hawaiian stock is well on the road to recovery (Balazs & Chaloupka 2004), and as result, it is listed as a population of 'Least Concern' on the IUCN red list (Pilcher et al. 2012). Reasons for decline of sea turtles are varied and depend on location. For example, key threats in the Commonwealth of the Northern Marianas include directed take, coastal

degradation and habitat destruction whereas beach erosion and environmental contaminants are greater risks in places such as Johnston Atoll (NMFS & USFWS 1998). Population declines in animals can be broadly explained either by excessive mortalities or failure of recruitment. The former is best understood by determining what is killing sea turtles whereas the latter is often done by monitoring nesting success. Understanding causes of mortality can help resource biologists focus on mitigating the most important factors causing decline in sea turtles. At the very least, mortality surveys highlight potential gaps in demographic knowledge of various sea turtle stocks.

Necropsies are a tool commonly employed to gain a greater understanding of causes of death in sea turtles (Flint et al. 2009), and there are essentially 3 ways this tool is implemented. The first is the case report describing a disease in-depth in a single or small numbers (<3) of individuals (Manire et al. 2008). Such studies are useful to highlight a new cause of mortality in a species but give few clues on demographic impact or temporal or geographic extent. The second is large-scale studies involving in-depth statistical analyses of large numbers (>1000) of strandings over many years (Casale et al. 2010). Large-scale studies provide extensive insight into spatial temporal patterns of various causes of death and potential demographic impacts; however, because of the sheer number of cases, such studies generally sacrifice in-depth analyses of individual animals at the cellular level simply because such scrutiny is logistically and financially prohibitive. The third type of necropsy study is a hybrid between case studies and large-scale analyses that gathers detailed necropsy data for relatively large (50 to 300) numbers of animals over multiple years. Whilst meaningful in-depth demographic inferences are seldom possible with hybrid necropsy surveys, they do provide more detailed baseline information that might otherwise be overlooked in large-scale studies.

In the insular Pacific, our knowledge of the health status of green turtles is most extensive for Hawaii. In a study involving >6000 stranded Hawaiian green turtles over 30 yr, the tumor disease fibropapillomatosis was the most important cause of stranding, followed by hook and line trauma, miscellaneous, gill-nets, boat strike, and shark predation (Chaloupka et al. 2008). The pathology and pathogenesis of FP in Hawaii has been well characterized (Aguirre et al. 1998, Work et al. 2004); however, we know less about the pathology and pathogenesis of non-FP causes of green turtle strandings in other Pacific islands, hence the objective of the present study.

## MATERIALS AND METHODS

From 1993 to 2011, carcasses or formalin-fixed tissues from stranded green turtles were submitted to the US Geological Survey's National Wildlife Health Center-Honolulu Field Station from several islands in the Central, Western, and South Pacific (Fig. 1). When tissues only were submitted, gross necropsy notes from field biologists along with photos were used to gain an assessment of body condition, stage of decomposition, and gross lesions. Decomposition status of carcasses was subjectively graded as 'excellent' (= euthanized turtles); 'good' (= clear eyes, intact scutes, normally colored organs, and no smell); 'fair' (= noticeable odor of decomposition but with relatively normal coloration of internal organs); or 'poor' (= rank smell, peeling scutes, discolored or gaseous organs, or bloating). Body condition was subjectively scored 'excellent' (= plastron rounded, ample coelomic fat of buttery consistency); 'good' (= plastron rounded to flat, moderate amounts of coelomic fat with buttery to serous consistency); 'fair' (= plastron flat, small amounts of coelomic fat with mostly watery consistency); 'poor' (= plastron concave, serous atrophy of coelomic fat or morbid obesity); 'emaciated' (= plastron markedly concave with degradation of cartilage leading sometimes to separation of plastron from carapace, no coelomic fat). Carcasses were weighed (kg), straight carapace length (SCL) (cm) measured with calipers, and body condition index ( $BCI = SCL/kg^3$ ) calculated (Bjorndal 1980).

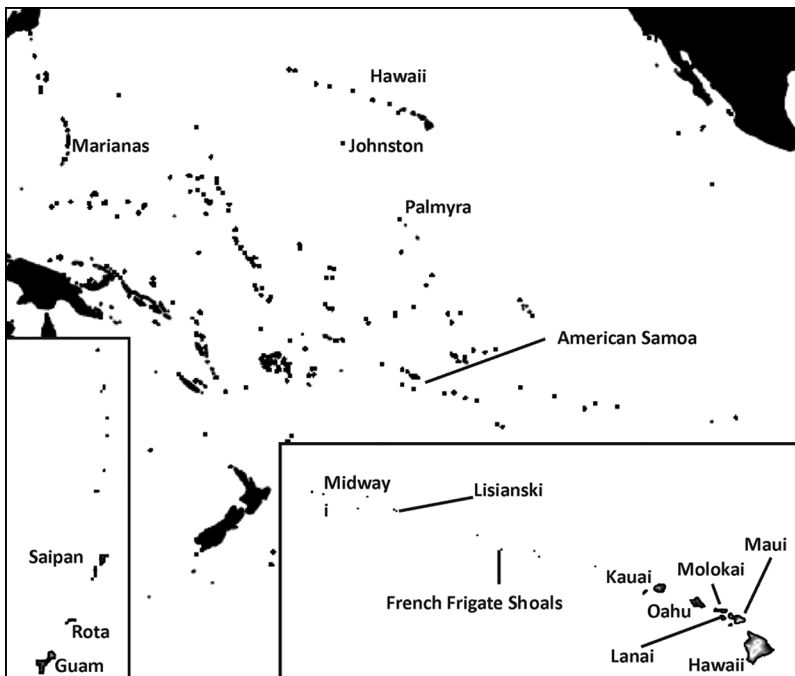


Fig. 1. Islands in the Central Pacific where green sea turtle *Chelonia mydas* samples originated. Insets at lower left and lower right are for Marianas and Hawaiian Islands, respectively

Formalin-fixed tissues were embedded in paraffin, sectioned at 5  $\mu\text{m}$ , stained with hematoxylin and eosin, and examined on light microscopy. As appropriate, special stains were used to detect fungi (Grocott's methenamine silver) or bacteria (Gram). Gross and microscopic lesions were used to determine causes of death that were broadly categorized as follows: 'trauma' (= gross evidence of entanglement or major fractures of skull or carapace or avulsion of limbs and associated hemorrhage); 'infectious/inflammatory' (= severe inflammation or necrosis of various internal organs with or without evidence of infectious agents such as viruses, bacteria, parasites, or fungi); 'nutritional' (= poor to emaciated body condition with gross or microscopic evidence of internal organ atrophy and no other evident lesions); 'physiologic' (= non-inflammatory disorders of anatomy or organ function not related to foreign bodies or nutrition); or 'unknown' (= no evident lesions that could explain cause of death). Trauma was further subcategorized as 'predation' (= gross evidence of interaction with predators such as avulsed limbs or butchery); 'entanglement' (= gross evidence of external interaction with fishing or mooring lines or fishing nets); 'impact'

(= gross evidence of blunt or acute trauma with boats or spears); or 'foreign body' (= gross evidence of gastrointestinal trauma secondary to ingestion of foreign material).

We used analysis of variance to compare carapace length and body condition index among diagnostic categories (trauma, inflammation, nutrition, physiologic, unknown).

## RESULTS

Of 230 turtles, 213 (93%) originated from the Hawaiian islands with the remainder from the Marianas (11 animals, 5%), American Samoa (4 animals, 2%), Palmyra and Johnston Atoll (2 animals, 1%). Of 153 known causes of death, trauma was most common (64%) followed by infectious/inflammatory (18%), nutritional (16%), and physiologic (1%) (Table 1). Unknown causes of death comprised 33% of all cases and seemed to be a function of post-mortem condition with unknown comprising 18%, 25%, 40%, and 58% of carcasses in excellent, good, fair, and poor post-mortem condition, respectively. For

Table 1. Causes of death in green sea turtles *Chelonia mydas* by islands, sex, straight carapace length (SCL, mean  $\pm$  SD) and body condition index (BCI, mean  $\pm$  SD; Bjørndal 1980). (-) condition not found; FFS: French Frigate Shoals

Variable	Infectious/ inflammatory	Nutritional	Physiologic	Trauma	Unknown	Total
<b>Hawaiian Islands</b>						
Hawaii	8	16	1	17	32	74
Lanai	-	-	-	1	-	1
Maui	2	-	1	11	4	18
Molokai	-	-	-	-	1	1
Oahu	11	3	-	60	29	103
Kauai	2	1	-	4	4	11
FFS	1	-	-	-	-	1
Lisianski	-	-	-	-	1	1
Midway	1	-	-	-	2	3
<b>Mariana Archipelago</b>						
Guam	1	-	-	-	-	1
Rota	-	-	-	1	-	1
Saipan	1	3	-	4	1	9
<b>Other islands</b>						
Palmyra	1	-	-	-	-	1
Johnston Atoll	-	1	-	-	-	1
Samoa	-	1	-	-	3	4
Grand total	28	25	2	98	77	230
<b>Turtle demographics</b>						
Female	18	13	2	47	40	120
Male	9	10	-	46	27	92
Unknown	1	2	-	5	10	18
SCL (n)	58.9 $\pm$ 19 (26)	55.3 $\pm$ 12.4 (25)	65.3 $\pm$ 9.5 (2)	57.9 $\pm$ 16.4 (97)	54.9 $\pm$ 14.3 (73)	
BCI $\times$ 1000 (n)	0.115 $\pm$ 0.017 (21)	0.112 $\pm$ 0.03 (22)	0.1598 $\pm$ 0.001 (2)	0.129 $\pm$ 0.019 (90)	0.1283 $\pm$ 0.019 (68)	

known diagnoses, size of turtles did not differ significantly ( $F = 0.38$ ,  $p = 0.77$ ,  $df = 149$ ) between categories; however, turtles in nutritional and infectious/inflammatory categories had significantly ( $F = 7.38$ ,  $p = 0.0001$ ,  $df = 134$ ) poorer body condition. Except for trauma, females tended to dominate each diagnostic category (Table 1).

Of 98 trauma cases, entanglement comprised a majority (33) followed by impact (25), predation (21), and foreign body ingestion (19). Of 33 external entanglements, 16 involved fishing line, 13 fishing nets, 2 hooks, and 1 each an inner tube and a buoy mooring line. Fishing line entanglement involved mainly the front flippers (10), neck (5), or combination thereof. Entanglement of flippers usually entailed partial to complete strangulation of the limb with concomitant edema and gangrenous necrosis sometimes leading to complete severance of humerus (Fig. 2A). Of 33 entanglements, 3 had evidence of linear erosion of intestinal mucosa secondary to fishing line ingestion (Fig. 2B). Impact trauma affected the shell and head equally (12 each). Shell trauma was mostly due to boat propeller strike and characterized by single to multiple parallel linear fractures of the carapace, whereas skull trauma was mostly associated with single to multiple puncture wounds compatible with pole spear (Fig. 2D) or skull fracture from impact by blunt object; 1 turtle had been shot in the head by a pellet gun. One turtle died from concussive blast due to proximity to explosives and had multiple hemorrhages within the body cavity. For all but 1 case (intestinal perforation of unknown cause), foreign body ingestion mostly involved fishing line that usually led to plication of small intestines with linear erosion of the mucosa. Of the 19 cases with foreign body ingestion, 10 had external evidence of fishing line interaction in the form of healed forelimb amputations, fishing line scars, or external hooks. Predation was most often ( $n = 18$ ) attributed to attacks from tiger sharks *Galeocerdo cuvier* characterized by traumatic amputation of limbs, tail, or head leaving wounds with jagged edges and multiple serrations. In 4 cases, semicircular ablation of the plastron and carapace exposing internal organs was evident (Fig. 2C), and this was usually accompanied by multiple irregular rake marks on the carapace and plastron. Three turtle carcasses were found with evidence of butchery by humans (carcass partially buried or found with partially flensed bones and straight linear gashes in bone or cartilage compatible with use of cutting implements).

Trauma cases had secondary complications. Fibropapillomatosis was seen in 6 instances of entanglement, 3 in predation, and 2 each of foreign body and

impact. Sepsis was seen in a case of entanglement and a case of foreign fishing ingestion, and severe diffuse fibrinous coelomitis was seen in 1 case of impact trauma. Sepsis and emaciation was seen in 1 case each of entanglement and foreign body ingestion.

Of the 28 inflammatory/infectious cases, the organ systems most often affected were gastrointestinal (7), whole body (6), hepatic, musculoskeletal, or pulmonary (3 each), ocular, reproductive (2 each) and cardiovascular or urogenital systems (1 each). Gastrointestinal lesions manifested grossly as fibrinous serositis sometimes accompanied by excess mucoid, hemorrhagic, or fibrinous exudates on the mucosa of the small or large intestines. Microscopy revealed partial to full thickness necrosis of the mucosa sometimes associated with microcolonies of Gram-negative rods. Whole body inflammation involved either septic animals or vascular trematodiasis. Sepsis was characterized grossly by miliary nidi of caseous material in one or multiple organs (brain, spleen, liver, lung) (Fig. 2E) with microscopic evidence of necrosis with mixed mononuclear to granulocytic infiltrates associated with microcolonies of Gram-negative bacteria in multiple organs. Vascular flukes as cause of death was characterized by animals in poor body condition with microscopic evidence of multiple organs manifesting necrosis associated with trematode eggs or adult spirorchid trematodes.

Three turtles had hepatitis revealed grossly as a 10 cm granuloma on the right liver lobe in 1 turtle and pale mottled liver in a second (no gross report was available for the third). Two turtles with hepatitis had microscopic evidence of multifocal necrosis one of which was associated with microcolonies of Gram-negative rods. A third turtle with hepatitis from Guam had microscopic evidence of multifocal necrosis mixed with macrophages and giant cells associated with fungi. Ocular lesions presented grossly as cloudy corneas associated with severe conjunctivitis and blepharitis manifesting as fibrinous plaques covering the upper and lower eyelids. Microscopy revealed full thickness necrosis or spongiosis of epidermis exemplified by cells manifesting cytoplasmic hyper-eosinophilia, karyorrhexis and pyknosis mixed with clumps of small basophilic rods that stained Gram-negative accompanied by perivascular lymphoid infiltrates and occasional syncytia in the dermis.

Two adult females had microscopic evidence of egg yolk coelomitis as evidenced by multiple mixed granulocytic/mononuclear foci of inflammation associated with globular material on the surface of multiple organs; one animal had gross evidence of free

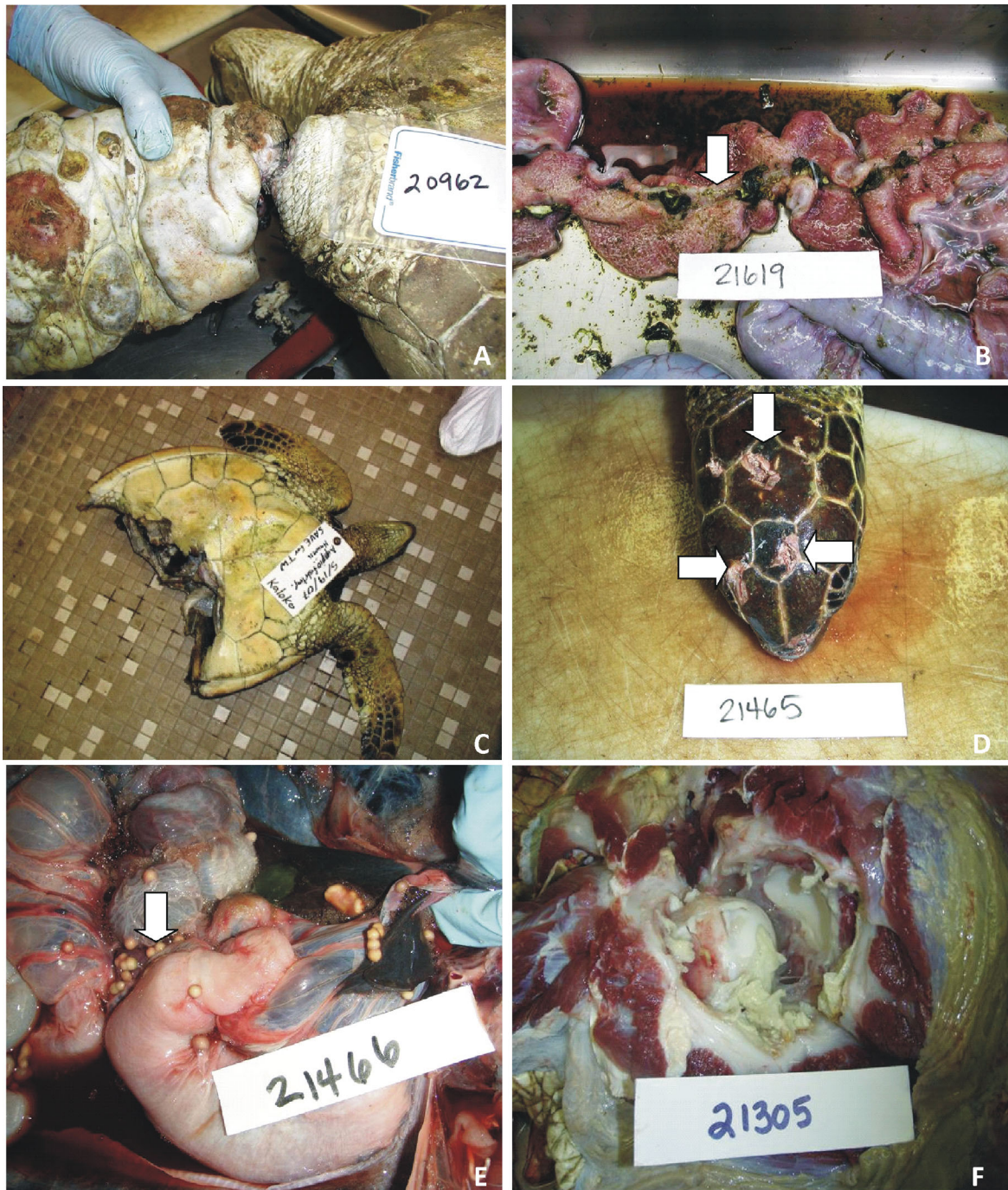

Fig. 2. Trauma of green sea turtles *Chelonia mydas*. (A) Fishing line strangulation of fore flipper — note marked swelling and edema, (B) fishing line-induced erosion of intestinal mucosa (arrow) manifesting hyperemia, (C) semi-circular ablation of caudal carcass caused by tiger shark predation, (D) multiple holes (arrows) in cranium secondary to 3-prong spear impact, (E) multiple abscesses in viscera, and (F) arthritis in multiple joints — note caseous material within joint

yolk in the coelomic cavity whereas gross necropsy data was incomplete for the other. Pulmonary lesions manifested grossly as miliary caseous lesions or grey discoloration with excessive mucus production in bronchiolar lumina. On microscopy, bronchiolar epi-

thelium was markedly hyperplastic with prominent submucosal red cell infiltrates mixed with melanized macrophages infiltrating spaces between epithelial cells and lamina propria. There was marked diffuse edema of the smooth muscle wall and clumps of

eosinophilic debris mixed with cluster of tiny basophilic rods (bacteria) within bronchiolar lumen and smooth muscle wall sometimes associated with mononuclear or giant cells.

Two turtles had polyarthritis involving axial and epaxial joints (Fig. 2F) and marked hypertrophy of skeletal muscles of limbs. On microscopy, joint cartilage manifested varying degrees of coagulation necrosis sometimes accompanied by mononuclear and giant cells. A third turtle from Palmyra manifested diffuse acute rhabdomyolysis of unknown origin. One turtle with cardiovascular disease had diffuse myocardial necrosis and inflammation characterized by large areas of myofibers exhibiting nuclear and cytoplasmic fragmentation accompanied by a prominent infiltrate of fibroblasts and mononuclear cells along with chronic epicarditis. One turtle with nephrosis had proximal tubules manifesting cytoplasmic swelling, fragmentation, and hypereosinophilia with karyolysis accompanied by multiple ill-defined focal deposits of pale basophilic wispy material (urates).

All but 1 turtle with nutritional problems were emaciated and manifested gross evidence of marked concavity of the plastron with some cases revealing degradation of cartilage leading to separation of the plastron from the carapace. Microscopy revealed severe atrophy of multiple organs including spleen, pancreas, heart, and liver. One turtle was morbidly obese and characterized by massive amounts of fat in the coelomic cavity. Two turtles died from cardiovascular collapse. One had a ruptured aortic aneurysm and another had a ruptured atrium. The cause of both was undetermined.

All turtles where histology was done had evidence of vascular fluke infection manifested by presence of variable numbers of trematode eggs surrounded by macrophages and giant cells in multiple organs or eosinophilic arteritis of the aorta associated with adult flukes or trematode eggs.

## DISCUSSION

Excluding FP as a primary diagnosis, trauma comprised a vast majority of causes of death in sea turtles in Hawaii and also played an important role in the Marianas, whereas starvation or disease seemed more common in Palmyra, American Samoa and Johnston. The findings of trauma in this study largely mirrored those of an analysis of a much larger set of green turtles from Hawaii (Chaloupka et al. 2008) that, after FP, found fishing line interactions, miscellaneous (mainly infections), gillnet, boat

strike, and shark predation as the most common causes of green turtle stranding in Hawaii. Our more detailed study of carcasses compared to the broader Hawaii survey (Chaloupka et al. 2008) sheds some light on fishing line interactions in Hawaii. Specifically, external entanglement can lead to gastrointestinal trauma secondary to fishing line ingestion in a small (ca. 9%) of cases which is somewhat higher than the 4% rate of linear foreign body erosion seen in loggerhead turtles from the Canary Islands (Orós et al. 2004). However, 48% of foreign body ingestion (virtually all of which were associated with gastrointestinal damage secondary to fishing line ingestion) had no external evidence of prior fishing line interaction (amputated limbs, fishing line scars). Thus, if one were to depend only on external exam of animals, one could underestimate almost half of fishing interactions thus emphasizing the importance of systematic internal exams of turtle mortalities. Furthermore, depending only on healed amputated forelimbs as an index of fishing line interaction can be misleading, because we were unable to differentiate these from healed shark bite avulsions, a natural cause of trauma. The use of Hawaiian slings or 3-pronged pole spears to kill sea turtles was another notable finding not previously documented with fishing interactions in Hawaii (Nitta & Henderson 1993, Chaloupka et al. 2008). Our diagnostic findings are also broadly in accordance with those of loggerhead turtles in the Canary Islands (Orós et al. 2005) where entanglement, boat impact, and foreign body ingestion comprised 24, 23, and 19% of known diagnoses, respectively. In contrast, natural predation from jaguars was a more significant cause of trauma for nesting female sea turtles in Costa Rica (Santoro et al. 2007).

Given that anthropogenic trauma was the most significant overall cause of death not associated with FP in green turtles in the Pacific, this presents opportunities to effect management that could decrease such impacts. For instance, implementation of slow or no speed zones for boats has been successful in reducing deaths from boat strikes of endangered manatees in Florida (Laist & Shaw 2006). The use of visual deterrents (Wang et al. 2010) to warn turtles away from gill nets, or more thorough monitoring and enforcement of gill net deployments to ensure that turtles can be rescued prior to drowning might reduce their impacts on sea turtles. Eliminating fishing line interactions could prove more difficult, because these activities, unlike longline fisheries (Work & Balazs 2010), are less regulated. However,

impacts of fishing line ingestion could be reduced by a combination of greater public education and outreach concomitant with creative solutions such as the use of biodegradable fishing lines. Most importantly, many Pacific Islands cultures have long traditions of careful management of marine resources, and even though many of these are waning with the advent of technology, their structural underpinnings persist (Johannes 1978); depending on how they are implemented, societal and peer pressure could be very effective tools to conserve turtles in the region and reduce anthropogenic impacts.

Infectious/inflammatory lesions made up the second most common cause of death in stranded turtles from the Central Pacific. These comprise the 'miscellaneous' category of a larger scale stranding study in Hawaii (Chaloupka et al. 2008) that was the third most common cause of sea turtle strandings. As in trauma, in-depth studies of carcasses sheds more light on just what comprises such mortalities. When lesions were partitioned by organ systems, we found the gastrointestinal tract or whole body to be mainly affected whereas the systems most affected in other geographic regions were the integumentary system in loggerhead turtles from Spain (Orós et al. 2005), the musculoskeletal system in nesting green turtles in Costa Rica (Santoro et al. 2007), and the whole body (systemic spirorchidiasis) in green turtles from Australia (Flint et al. 2010). Gastrointestinal lesions in our study typically manifested as bacterial enteritis or mucosal necrosis. In sea turtles from the Canary Islands, non-fishing line-induced intestinal lesions have been associated with bacteria (Orós et al. 2005) or helminths (Orós et al. 2004) Whilst spirorchids are common histological findings in green turtles in Hawaii (Aguirre et al. 1998), we seldom found this to be a primary cause of death in contrast to turtles from Australia where they are a major cause of death in green turtles (Flint et al. 2010). Hepatitis was uncommon in our study and lesions were similar to those of marine turtles in Spain (Orós et al. 2004). The single case of mycotic hepatitis confirmed that mycotic infections are isolated events usually involving immunocompromised animals (Lewbart & Medway 1993, Manire et al. 2002, Orós et al. 2011). We were unable to confirm the cause of the ocular lesions seen in 2 turtles; ocular lesions were associated with bacteria in Spanish loggerheads (Orós et al. 2005) and herpes viruses in green turtles from Florida (Jacobson et al. 1986). Both cases of arthritis presented with marked hypertrophy of muscles of the fore flippers and hind flippers and clinical manifestation of stiffness. No evidence of infectious agents were seen and none

were cultured (data not shown); however, the multicentric nature of these arthritis cases lead us to suspect either immune disorder or unidentified infectious agent leading to systemic inflammation of the axial and epaxial skeleton. To date, described cases of arthritis in sea turtles have been localized to a single limb (Greer et al. 2003, Raidal et al. 2006). Egg yolk coelomitis was infrequent and unusual for wild turtles; this condition is more often associated with reproductive irregularities or abnormal nesting in captive reptiles (Stacy et al. 2008, Gardner & Barrows 2010, Mans & Sladky 2012).

Emaciation comprised the third most common cause of death. All emaciated turtles had varying degrees of infestation with vascular flukes, however, microscopic lesions of trematodiasis did not appear more severe than those present in other mortality categories (trauma, infectious). Previous studies have shown a negative relationship between parasite burden and body condition (Work et al. 2005) so parasite burden is likely exacerbated with emaciation. Cachexia was a significant contributor to strandings of loggerheads in Spain (Orós et al. 2005). The one morbidly obese turtle was found dead in a boat harbor with a stomach full of fish scraps. Fishermen had observed this animal to be a resident in the harbor, and we suspect that a chronic protein-rich diet led to the obesity. The cause of the aortic and atrial aneurysm in 2 turtles could not be determined. In Australia, this condition has sometimes been associated with vascular flukes in green turtles (Flint et al. 2009).

Understanding causes of death in wild marine turtles in tropical climes poses challenges such as logistical difficulties of detecting dead individuals that are in suitable condition to necropsy, having someone on site to carry out a necropsy, and shipping samples from remote islands to Honolulu for laboratory work up. In some cases, the availability of only formalin-fixed tissues precluded ancillary tests such as cultures. Despite these limitations, doing necropsies on animals is a relatively low-cost/low technology activity that lends itself well to places with little infrastructure and that can yield useful information on causes of death. Scientific findings from such activities could potentially translate to conservation action. It is also encouraging that there is no evidence of FP in turtles from the islands we examined other than Hawaii. We are hoping by this summary to encourage biologists and resource managers in other islands of the Pacific such as French Polynesia and Micronesia to be vigilant and investigate turtle strandings in order to gain a better appreciation of the health status of their turtle stocks.

*Acknowledgements.* The authors thank Bob Rameyer, Renee Breeden, Marc Rice, Skippy Hau, Don Heacock and Shandell Brunson for assistance. Mention of products or trade names do not imply endorsement by the US Government.

## LITERATURE CITED

- Aguirre AA, Spraker TR, Balazs GH, Zimmerman B (1998) Spirochidiasis and fibropapillomatosis in green turtles from the Hawaiian islands. *J Wildl Dis* 34:91–98
- Balazs GH, Chaloupka M (2004) Thirty-year recovery trend in the once depleted Hawaiian green turtle stock. *Biol Conserv* 117:491–498
- Bjorndal KA (1980) Nutrition and grazing behavior of the green turtle *Chelonia mydas*. *Mar Biol* 56:147–154
- Casale P, Affronte M, Insacco G, Freggi DV and others (2010) Sea turtle strandings reveal high anthropogenic mortality in Italian waters. *Aquat Conserv Mar Freshw Ecosyst* 20:611–620
- Chaloupka M, Work TM, Balazs GH, Murakawa SKK, Morris RM (2008) Cause-specific temporal and spatial trends in green sea turtle strandings in the Hawaiian Archipelago (1982–2003). *Mar Biol* 154:887–898
- Flint M, Patterson-Kane JC, Limpus CJ, Work TM, Blair D, Mills PC (2009) Postmortem diagnostic investigation of disease in free-ranging marine turtle populations: a review of common pathologic findings and protocols. *J Vet Diagn Invest* 21:733–759
- Flint M, Patterson-Kane JC, Limpus CJ, Mills PC (2010) Health surveillance of stranded green turtles in southern Queensland, Australia (2006–2009): an epidemiological analysis of causes of disease and mortality. *EcoHealth* 7: 135–145
- Gardner BR, Barrows MG (2010) Yolk coelomitis in a white-throated monitor lizard (*Varanus albigularis*). *J S Afr Vet Assoc* 81:121–122
- Greer LL, Strandberg JD, Whitaker BR (2003) *Mycobacterium chelonae* osteoarthritis in a Kemp's ridley sea turtle (*Lepidochelys kempii*). *J Wildl Dis* 39:736–741
- Jacobson ER, Gaskin JM, Roelke M, Greiner EC, Allen J (1986) Conjunctivitis, tracheitis, and pneumonia associated with herpesvirus infection in green sea turtles. *J Am Vet Med Assoc* 189:1020–1023
- Johannes RE (1978) Traditional marine conservation methods in Oceania and their demise. *Annu Rev Ecol Syst* 9: 349–364
- Laist DW, Shaw C (2006) Preliminary evidence that boat speed restrictions reduce deaths of Florida manatees. *Mar Mamm Sci* 22:472–479
- Lewbart GA, Medway W (1993) A case of mycotic lung disease in a wild caught juvenile sea turtle. *J Small Exotic Anim Med* 2:58–59
- Manire CA, Rhinehart HL, Sutton DA, Thompson EH, Rinaldi MG, Buck JD, Jacobson E (2002) Disseminated mycotic infection caused by *Colletotrichum acutatum* in a Kemp's ridley sea turtle (*Lepidochelys kempii*). *J Clin Microbiol* 40:4273–4280
- Manire CA, Stacy BA, Kinsel MJ, Daniel HT, Anderson ET, Wellehan JXF Jr (2008) Proliferative dermatitis in a loggerhead turtle, *Caretta caretta* and a green turtle, *Chelonia mydas*, associated with novel papillomaviruses. *Vet Microbiol* 130:227–237
- Mans C, Sladky KK (2012) Diagnosis and management of oviductal disease in three red-eared slider turtles (*Trachemys scripta elegans*). *J Small Anim Pract* 53: 234–239
- Nitta E, Henderson J (1993) A review of interactions between Hawaii's fisheries and protected species. *Mar Fish Rev* 55:83–92
- NMFS & USFWS (1998) Recovery plan for US Pacific populations of the green turtle (*Chelonia mydas*). NMFS, Silver Spring, MD, [www.nmfs.noaa.gov/pr/pdfs/recovery/turtle\\_green\\_pacific.pdf](http://www.nmfs.noaa.gov/pr/pdfs/recovery/turtle_green_pacific.pdf)
- Orós J, Déniz S, Calabuig P (2004) Digestive pathology of sea turtles stranded in the Canary Islands between 1993 and 2001. *Vet Rec* 155:169–174
- Orós J, Torrent A, Calabuig P, Déniz S (2005) Diseases and causes of mortality among sea turtles stranded in the Canary Islands, Spain (1998–2001). *Dis Aquat Org* 63: 13–24
- Orós J, Calabuig P, Arencibia A, Camacho M, Jensen HE (2011) Systemic mycosis caused by *Trichophyton* spp. in an olive ridley sea turtle (*Lepidochelys olivacea*): an immunohistochemical study. *NZ Vet J* 59:92–95
- Pilcher NJ, Chaloupka MY, Woods E (2012) *Chelonia mydas* (Hawaiian subpopulation). [www.iucnredlist.org](http://www.iucnredlist.org) (accessed 9 May 2015)
- Raidal SR, Shearer PL, Prince R (2006) Chronic shoulder osteoarthritis in a loggerhead turtle (*Caretta caretta*). *Aust Vet J* 84:231–234
- Santoro M, Morales JA, Rodríguez-Ortiz B (2007) Spirochidiosis (Digenea: Spirochiidae) and lesions associated with parasites in Caribbean green turtles (*Chelonia mydas*). *Vet Rec* 161:482–486
- Stacy BA, Howard L, Kinkaid J, Vidal JD, Papendick R (2008) Yolk coelomitis in Fiji Island banded iguanas (*Brachylophus fasciatus*). *J Zoo Wildl Med* 39:161–169
- Wang JH, Fislis S, Swimmer Y (2010) Developing visual deterrents to reduce sea turtle bycatch in gill net fisheries. *Mar Ecol Prog Ser* 408:241–250
- Work TM, Balazs GH (2010) Pathology and distribution of sea turtles landed as bycatch in the Hawaii-based North Pacific pelagic longline fishery. *J Wildl Dis* 46: 422–432
- Work TM, Balazs GH, Rameyer RA, Morris R (2004) Retrospective pathology survey of green turtles (*Chelonia mydas*) with fibropapillomatosis from the Hawaiian Islands, 1993–2003. *Dis Aquat Org* 62:163–176
- Work TM, Balazs GH, Schumacher J, Marie A (2005) Epizootiology of spirochid infection in green turtles (*Chelonia mydas*) in Hawaii. *J Parasitol* 91:871–876

*Editorial responsibility:* Alex Hyatt, Geelong, Victoria, Australia

*Submitted:* November 24, 2014; *Accepted:* June 9, 2015  
*Proofs received from author(s):* July 22, 2015