

A Simple Humane Method to Euthanize a Sea Turtle

Thierry M. Work¹ & George H. Balazs²

¹U.S. Geological Survey, National Wildlife Health Center, Honolulu Field Station, PO Box 50167, Honolulu, HI 96850 USA (E-mail: thierry_work@usgs.gov); ²NOAA-NMFS-Pacific Islands Fisheries Science Center, 2570 Dole St., Honolulu, HI 96822 USA (E-mail: gbalazs@honlab.nmfs.hawaii.edu)

Increased interconnectedness, communication, and demands of society require that wildlife professionals make every effort to consider animal welfare when handling animals. The challenge can be daunting, particularly when a wild animal needs to be euthanized. In some cases, biologists are in remote areas under conditions that may be less than ideal to properly and swiftly dispatch an animal, either because of a lack of proper supplies or veterinary training. Societal demands for consideration of animal welfare are not limited to wildlife professionals. Native cultures, fishermen and hunters have traditional methods of capturing or killing wildlife that are now under increasing public scrutiny. A current example is in Australia where aborigines were criticized for the practice of dispatching sea turtles by throwing a cement block at the animals' heads resulting in negative public reaction (Queensland Times 2010).

Of the vertebrates, reptiles and amphibians pose particular challenges for euthanasia because their brain can withstand long periods of anoxia, and it is difficult to tell when they are dead (Mader 1996). Approved methods for euthanasia of reptiles include injectable anesthetics, carbon dioxide, captive bolt impact to the brain, or gunshot to the head. Decapitation, drowning or a simple blow to the head (stunning) are not humanely acceptable as the brain can continue to function separately from the body for some time. The main goal of euthanasia is the rendering of immediate and irreversible unconsciousness followed by loss of brain, cardiac, and respiratory function with minimal distress and anxiety (AVMA 2007). Injectable anesthetics, carbon dioxide, captive bolt, or the use of guns require specialized training and supplies that may not be available in remote settings, and some of these (injectable euthanasia solutions) have strict legal controls limiting their use to licensed veterinarians. Furthermore, once injected, euthanasia solutions render the carcass unfit for human consumption, which is a consideration for native people, fishermen and hunters who may consume the carcass. Anesthetics also pose a challenge for disposal due to the potential for secondary intoxication.

Sea turtles are routinely consumed throughout the world. Sometimes, butchering of animals takes place immediately after capture, while the animal is still alive, and this practice is considered inhumane. We outline here a simple method to rapidly euthanize a sea turtle that requires a minimum of equipment and training. This technique ensures destruction of the brain and eliminates all possibility that the animal can perceive pain during the butchering process.

Recommended equipment includes a heavy (≥ 5 kg) sledge hammer and a pointed chisel with a hand guard collar. The turtle's head is positioned and a chisel point is placed over the central scute (Fig. 1A). A swift blow to the chisel with the sledge hammer causes the chisel to penetrate the brain case and pulverize the brain (Fig. 1B-D). We first used this technique on five freshly dead specimens of Hawaiian green turtles (*Chelonia mydas*) ranging in size from 54

to 80 cm straight carapace length (SCL). We swiftly and successfully penetrated the brain case after 1-3 blows delivered over less than 5 seconds. In an unexpected but emergency humane situation, we used this technique on an 88 cm SCL living but partially butchered green turtle brought to one of us (GHB) by enforcement authorities. This technique resulted in penetration of the brain case with instant loss of consciousness as evidenced by a lack of corneal reflex. Beveled chisels, lighter hammers, and holding the hammer in the classic fulcrum position (as opposed to position seen in Fig. 1B) resulted in less control of the procedure and incomplete penetration of the skull. To ensure the maximum likelihood of success with this technique, the following should be done:

Restraint: The head must be still for proper placement of the chisel and penetration of the brain case. It is critical that the head is placed on a firm surface such as a cement block, concrete or a flat rock but not on sand or loose dirt. This is to ensure that the entire force of the hammer blow to the chisel translates to penetration of the skull and is not dissipated in loose substrate.

Placement of chisel: Placing the chisel point at the location in Fig. 1A ensures it will always penetrate the brain case and pulverize the brain. The chisel should be perpendicular to the head.

Sledge hammer: Turtle skulls are remarkably elastic, resilient, and resistant to perforation. To ensure success, it is critical to use a suitably heavy sledge hammer (5 kg minimum) and to hold it in such a way that maximal force is immediately applied to the chisel (Fig. 1B). The hammer should be raised to at least 1+ m above the chisel and rammed straight down with the maximum velocity that the handler can muster. One to three blows should suffice to penetrate the cranium and brain of even the largest turtle.

Chisel: The chisel should be stout (> 2 cm wide) and have a sharp point (Fig. 1A inset) to ensure that the entire force of the sledge hammer is concentrated on a small area thus maximizing the chances of penetration. Routine sharpening of the chisel point with a file after each use is recommended.

Size of the turtle: In younger animals, the seams of the skull bones are not fully fused, so this technique will typically split the skull down the middle (sagittal) (Figs. 1B-C). This is not the case in adults where the skull is more heavily ossified and thus remains intact. Accordingly, the force needed to penetrate a juvenile skull will be less than that for an adult; however, to be conservative and to ensure penetration of the brain case, we used the maximal force possible regardless of size class.

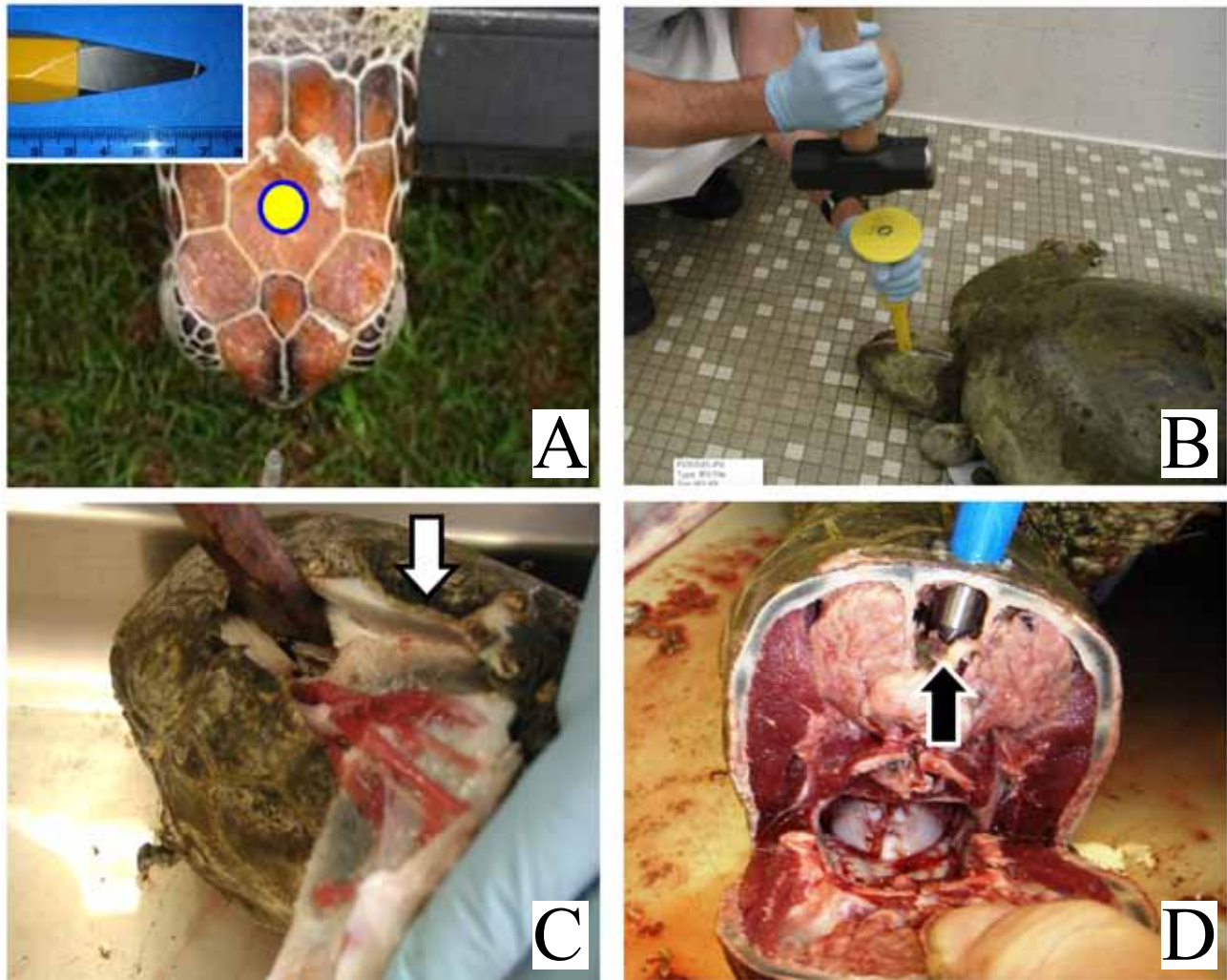


Figure 1. A) Location of chisel point (yellow) with chisel point and scale bar (cm). B) Penetration of the skull with the chisel. For maximum effectiveness and force, the sledge hammer must be held as shown. C) Post impact. Note that the skull is split down the center in this juvenile (arrow). D) Cut away view of the skull penetrated by chisel. Note the complete ablation of the brain by chisel within brain case.

Although all turtles tested were green turtles, we believe this technique may be applied equally effectively in other turtle species with appropriate training and modifications. When applying this to other species, we recommend practicing on carcasses first. The necessary supplies are simple and readily accessible in most parts of the world. We recognize that euthanasia is a difficult issue with no easy solution. Additionally, when this activity is performed in the wild, public perception should be taken into consideration; however the most appropriate method of informing/educating bystanders should be evaluated on a case by case basis and was not discussed here because it was beyond the scope of the manuscript. Ideally, euthanasia should be performed by a qualified professional using injectable drugs, but these drugs often require at least 30 min to take effect in reptiles (AVMA 2007) and render the carcass unfit for human consumption. For traditional harvesting, this is not an option, and with proper supplies and practice, our technique offers a reasonable alternative.

Acknowledgments: Mark Flint BVsc, T. Todd Jones, Bob Braun DVM, Bob Morris DVM, Daniel Mulcahy DVM, and Greg Levine DVM provided constructive comments on previous versions of this manuscript. Mention of products or trade names does not imply endorsement by the US Government.

AVMA. 2007. AVMA guidelines on euthanasia. American Veterinary Medical Association. 36pp.

MADER, D.R. 1996. Euthanasia and necropsy. In: Mader, D.R. (Ed.) Reptile Medicine and Surgery. Saunders, Philadelphia, pp. 277-281.

Queensland Times, 2010. Turtle slaughter raises questions. <http://www.qt.com.au/news/turtle-slaughter-raises-questions/505974/> (accessed October 2012).