

4.

Fibro-epithelial Growths of the Skin in Large Marine Turtles,
Chelonia mydas (Linnaeus).

G. M. SMITH

Department of Anatomy, Yale School of Medicine,
and New York Aquarium

&

C. W. COATES

New York Aquarium

(Plates I-XVIII).

Diseases of turtles have received but relatively little study up to the present time and not much is known about the benign or malignant tumors of these reptiles. In a report on the causes of deaths in the London Zoological Gardens, Plimmer (1912, 1913) reported two cases of such growths. Scott and Beattie (1927), referring to Plimmer's observation, state that one tumor was a glandular cancer of the stomach in an elephantine tortoise and that the second was a multi-nucleated tumor involving heart muscle of *Sternotherus niger*, a fresh water turtle from the Cameroon area of West Africa. These authors point out that of six thousand reptiles of various kinds autopsied at the London Zoological Gardens, only two showed tumors as the cause of death. Pick and Poll (1903) described an adenomatous growth of the thyroid of the Brazilian fresh water turtle, *Platemys geoffroyana* (*Hydraspis geoffroyana*). This was a large mass measuring 6 x 4 x 2.5 cm., consisting of narrow cylindrical cells in small acinar arrangement with lumina containing granular material.

In December, 1936, it came to our attention that one of the large marine turtles, *Chelonia mydas* (Linnaeus), of the New York Aquarium presented multiple warty growths of the skin. This turtle, shipped from Key West, Florida, two years previously, occupied a large harbor water tank with two others of the same species and with two large loggerhead turtles, *Thalassochelys caretta* (Linnaeus). None of the other four turtles exhibited papillomatous lesions, although an exposure to possible infection had existed for more than a year. The water supply of the tank is a continuous flow of harbor water, which is brackish and changes density with the change of tide.

The turtle showing multiple warts weighed approximately one hundred and fifty pounds. Papillomata were distributed in the region over the dorsal part of the neck in both non-pigmented and pigmented areas and in the light gray or whitish areas of both axillae and both groins (Figs. 1 and 2). There were in addition several small warty excrescences in the outer regions of the upper eyelids involving the conjunctivae. Tissues were

removed from the neck for microscopic study and a month later more tissues were excised from several sites for transplantation experiments.

Recently (December, 1937) it was determined that cutaneous fibro-epithelial growths occur in *Chelonia mydas* (Linnaeus) under normal conditions of wild life. Three instances of this disease were found in these large marine turtles (weighing from sixty to two hundred pounds) in the course of an examination of some two hundred turtles of this species caught in the waters south of Key West. The distribution of the growths in the wild turtles likewise occupied the dorsal aspect of the neck, the axillae, groins and eyelids. The histological details of the lesions in the wild turtle resembled in general those of the original turtle studied in the New York Aquarium and it was thought probable that the disease in wild life and that seen in the Aquarium represented the same condition.

For purposes of pathological description, the cutaneous growths of the large marine turtle now under consideration may be referred to as fibro-epithelial in character. There appeared to be considerable variety in the size, form and arrangement of the masses of tissue (Figs. 3 to 8). Outstanding were the papillary, coral or cauliflower-like growths (Figs. 5 to 8). Figure 7 represents a growth arising from non-pigmented skin, while the tumor in Fig. 8 is derived from a pigmented area. Less frequently smooth oval or round fibromata projected above the level of the skin (Figs. 12 and 13). Both papillomata and fibromata, caused perhaps by the same agent, appeared as single or confluent masses in the same turtle. Papillomata and fibromata at times grew in immediate apposition. All growths had a firm gritty consistency and areas of calcification at the surface of tumors were not uncommon. In the preparation of histological sections, it was found advisable to subject all tissues to decalcification. Papillomata varied in size from 3 mm. to 3 cm. while solitary fibromata measured as much as 2.5 cm. in diameter.

The internal structure of papillary growths became clear on sectioning the gross specimens and inspecting their cut surfaces (Figs. 9 to 11). Attached to the skin by a sessile or pedunculated base, the stroma of the various growths was composed of dense intermingling fibrous tissue which spread out toward the surface in many lesser ramifications to form rounded, bulbous or pointed terminal tips covered with thickened surface epithelium.

The microscopic structure of normal skin of *Chelonia mydas* is shown in Fig. 17. Compared with this the epithelium covering papillomata appeared to be somewhat thickened and covered with an irregular mass of keratin (Fig. 21). The size and shapes of epithelial cells varied greatly and intercellular bridges of prickle cells were strongly developed (Fig. 23). Epithelial columns and cords often dipped down deeply into the supporting stroma (Fig. 22). So-called epithelial "pearls" were frequently encountered, not unlike those found in mammalian epithelial tumors (Fig. 24). The vascular supply of papillomata is a network of small blood vessels. It was not unusual to have collections of lymphocytes grouped around small blood vessels, indicating possibly a low grade of inflammation (Fig. 27). Cell inclusions were not demonstrated in the sections examined. Dendritic pigment cells frequently accompanied blood vessels (Fig. 25), or they existed in diffuse distribution in the stroma below the surface epithelium (Fig. 26). In highly pigmented areas, numerous melanophores were found at the surface between epithelial cells.

The fibromata of the turtle's skin (Figs. 12 and 13) were relatively simple in microscopic architecture, being composed of intermingling bands of fibrous tissue varying in density (Figs. 28 and 29), covered on the surface with but slightly thickened epithelium (Fig. 28). Although the skin covering fibromata could appear non-pigmented so that tumors looked white on external examination, the interiors were usually gray or a streaky black due to the presence of pigment cells which followed the course of blood

vessels (Fig. 28). Small nerve trunks were found in one of the sections of a fibroma (Fig. 30).

It was noted that papilloma and fibroma existed at times in a combined form of tumor. This was illustrated very well in a large growth measuring 8 x 6 x 5 cm., taken from the right side of the neck of one of the Key West turtles (Fig. 15). The large bosses (F) of this growth were fibromata, while at point P a distinct papilloma existed, fused with the rest of the mass. Figure 16 shows the interior of this tumor to be composed of five smaller fibromata, white or partly pigmented. Nearly all fibromata showed microscopic evidences of peri-vascular melanophores (Fig. 28).

These fibro-epithelial tumors of the turtle show no malignant changes. Mitotic figures are few in number.

COMMENT.

The stimulus to the formation of cutaneous fibro-epithelial growths in *Chelonia mydas* remains for the present undetermined. It is interesting to note that fishermen of the white population at Key West, exposed for many years to the sun, frequently develop keratoses and malignant changes of the skin, whereas it is said that with fishermen of the colored population such changes are rare occurrences. It is conceivable that these great sea turtles, even though in an aquatic environment, may respond to exposure to the sun prolonged over many years by papillomatous changes affecting the skin. A different explanation for the etiology of the disease other than the above mentioned is more likely, such as infection by parasites or by an unknown virus. No parasites were noted so far in the tumor tissues of the four turtles examined. It is known that certain infectious warts of man, dog and cattle are of virus origin. Infectious papillomatosis of rabbits has been shown by Shope (1933) and Rous and Beard (1934) to have its origin in a virus. Such an etiology for the cutaneous turtle fibro-papilloma is not unlikely. The study of the transmissibility of the turtle papilloma has been begun and it is hoped to report on this at a later date.

SUMMARY.

Cutaneous fibro-epithelial growths in four large marine sea turtles, *Chelonia mydas* (Linnaeus), are described, with a discussion of their microscopic structure.

BIBLIOGRAPHY.

- PICK, L. and POLL, H.
1903. Ueber einige bemerkenswerthe Tumorbildungen aus der Thierpathologie, insbesondere über gutartige und krebsige Neubildungen bei Kaltblütern. *Berlin Klin. Woch.* 24:547.
- FLIMMER, H. G.
1912. Report on the deaths which occurred in the Zoological Gardens during 1911. *Proceedings of the Zoological Society of London.* 1:235.
1913. Report on the deaths which occurred in the Zoological Gardens during 1912, together with the blood-parasites found during the year. *Proceedings of the Zoological Society of London.* 1:141.
- ROUS, P. and BEARD, J. W.
1934. A virus induced mammalian growth with characters of a tumor (the Shope rabbit papilloma). *Journ. of Exper. Med.* 60:701.

- SCOTT, H. H. and BEATTIE, J.
1927. Neoplasm in a Porose Crocodile. *Journal of Pathology and Bacteriology*. 30:61.
- SHOPE, R. E.
1933. Infectious papillomatosis of rabbits. *Journ. of Exper. Med.* 58:607.

EXPLANATION OF THE PLATES.

PLATE I.

- Figs. 1 & 2. Marine turtle, *Chelonia mydas*, weighing about 150 pounds, showing distribution of papillomata on neck, axillae and eyelid.

PLATE II.

- Fig. 3. Small papillomata. A pigmented growth at x.
Fig. 4. Papillomata of various shapes. E is tissue removed from upper eyelid with papilloma growing on the margin of eyelid.

PLATE III.

- Figs. 5 & 6. Larger forms of papillomata.

PLATE IV.

- Fig. 7. One of the larger forms of papillomata. Shows papilloma arising from non-pigmented skin.

PLATE V.

- Fig. 8. One of the larger forms of papillomata. Shows papilloma derived from pigmented skin.

PLATE VI.

- Fig. 9. Cut surfaces of gross specimens of papillomata.

PLATE VII.

- Fig. 10. Cut surface of gross specimen of papilloma.
Fig. 11. Cut surface of gross specimen of papilloma, showing a deeply pigmented stroma.

PLATE VIII.

- Fig. 12. Solitary fibroma of the skin, F marks the fibroma; C marks the site of a calcified plaque of the skin.
Fig. 13. Solitary fibromata of the skin.

PLATE IX.

- Fig. 14. Inner surfaces of fibromata with pigmentation.

PLATE X.

- Fig. 15. Large fibromatous masses, FF, with associated papilloma, P.

PLATE XI.

- Fig. 16. Interior of tumor shown in Fig. 15, exhibiting smaller fibromata; 1, 2, 3, 4 and 5.

PLATE XII.

- Fig. 17. Normal skin of *Chelonia mydas*. x 80.
Fig. 18. Papilloma with broad base of fibrous tissue supporting irregularly-shaped papillary processes tipped with thickened epithelium. x 40.

PLATE XIII.

Figs. 19 & 20. Low power magnification of papillomatous tissue. x 20.

PLATE XIV.

Fig. 21. Bulbous tips of a papilloma. Stroma slightly hyalin in character. x 100.
 Fig. 22. Surface epithelium of papilloma illustrating down-growth of epithelium, x 60.

PLATE XV.

Fig. 23. Surface epithelium of papilloma showing prickle cells united by thick intra-cellular bridges. Masson stain. x 650.
 Fig. 24. Deep-lying epithelial cord with epithelial "pearl." x 250.

PLATE XVI.

Fig. 25. Section from a papilloma with melanophores arranged around small blood vessels. x 125.
 Fig. 26. Melanophores in diffuse arrangement lying in stroma close to epithelium. x 200.

PLATE XVII.

Fig. 27. A collection of lymphoid cells around blood vessels in a papilloma. x 350.
 Fig. 28. Section taken from solitary pigmented fibroma showing compact fibrous tissue below skin. Numerous pigment cells accompany blood vessels. x 50.

PLATE XVIII.

Fig. 29. Dense, wavy, hyalin, fibrous tissue taken from the center of a non-pigmented fibroma.
 Fig. 30. In center of photograph a small nerve trunk traversing loosely arranged fibers of a fibroma. x 275.

SMITH & COATES.

PLATE I.

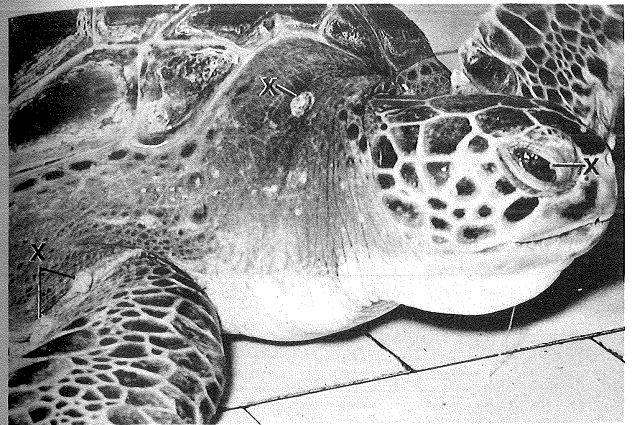


FIG. 1.

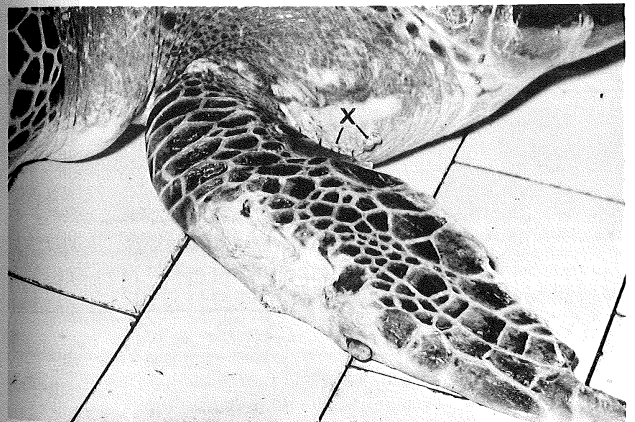

FIG. 2.

FIBRO-EPITHELIAL GROWTHS OF THE SKIN IN LARGE
 MARINE TURTLES, *CHELONIA MYDAS* (LINNAEUS).