

Marine Turtle Strandings Due to Spear, Gunshot, Arrow,
and Puncture-related Trauma in the Hawaiian Islands, 1982–July 2013

A report prepared by

Devon Francke and MTRP Staff

Marine Turtle Research Program
Protected Species Division
NOAA Pacific Islands Fisheries Science Center

August 1, 2013

70 of 6,584 (1.1%) Marine Turtle Strandings Due to Spear, Gunshot, Arrow, and Puncture-Related Trauma in the Hawaiian Islands, 1982 - July, 2013

DATE	ISLAND	LOCATION	SPECIES	SEX	SCL (cm)	CCL (cm)	TUMOR RANK	CAUSE OF STRANDING	END TURTLE STATUS	STRANDING DESCRIPTION	NECROPSY REPORT
04/04/82	OAHU	Sunset Beach	CM	U	41.3	-	0	Spear	Dead	Confiscated from suspect by Honolulu Police Department. Small spear hole in the head and HF. Died the following day.	Stomach contained Pterocloidia.
04/05/82	OAHU	Mokuleia (Dillingham Airfield)	CM	U	-	57.5	0	Spear	Dead	Picked up dead by NMFS-LE personnel after reported being found in the surf with a spear stuck in its head. Massive hemorrhage to the R. eye.	Stomach contents: 95% Amansia and 5% Turbinaria.
07/09/82	OAHU	Kailua Bay (Lanikai)	CM	U	33.6	-	0	Spear	Dead	Found alive in lethargic state with a spear hole in the R. side of the head with the R. eye bulging. Died on 7-27-82 at the NMFS-KRF. Reared in captivity then tagged and released at Bellows Beach, Oahu on 9-15-81.	No additional comments.
11/14/82	OAHU	Kahe Point	CM	U	-	91	0	Spear	Dead	Found dead with a spear hole in its neck wedged between rocks in water 40' deep.	No additional comments.
02/11/83	OAHU	Kaneohe Bay	CM	U	-	-	0	Spear	Dead	Found dead with a spear hole in the R. side of the neck floating near buoy #13.	Stomach filled with Codium sp.
10/13/83 Turtle ID: 5484	HAWA	South Point	CM	F	-	-	-	Gunshot	Dead	Tags 5485 and 5487 sent with letter. Reported that turtle was found dead washed ashore "dead because of a bullet shot in the head and another penetrating shot in the neck". Turtle was reportedly found in July.	No additional comments.
04/28/85	OAHU	Hanauma Bay	CM	M	38	39.6	0	Spear	Dead	Found dead floating with a small spear hole in ventral neck.	Spear hole in ventral neck, not very deep, but may have injured hyoid apparatus. Fuzz and particles of undigested Codium in feces. Clean carapace and plastron, no SB. Flipper scales sloughing. Green algae on pelvis and plastron. Lots of green fat. Tissue, Codium, and beak in stomach. Intestine contains monofilament snarls and bits of plastic. Samples: R. humerus, carapace, heart, lungs, liver preserved for Stemmermann, small amounts of Codium, and photo taken.
05/20/85	MOLO	Unknown	CM	U	-	-	-	Spear	Alive	Report of a turtle with encrusted tags "floundering" near shore. Also, had a spear hole.	No additional comments.
06/22/85 Turtle ID: 8491	OAHU	Kaneohe Bay (Kahaluu)	CM	F	58.9	63	-	Spear	Dead	Found alive, disoriented and lethargic in shallow water close to shore with two spear holes in its head, patched over with silicone cement. Died after being held in captivity at NMFS-KRF for 5 days.	2 holes patched over with silicone cement. Thumb-size tumors on ventral FF, small on eyes, neck, and inguinal. BB fore of FF. Many SB. Thick layer of fat. Moderate fill in stomach and intestine. Black fibrous particles present, probably plastic. Samples: stomach contents and fibrous sample saved.
07/10/85	OAHU	Waikiki Beach	CM	U	-	-	-	Spear	Dead	Found shot with a spear gun. "A witness said it was brought ashore by a young man who, when told by spectators to put it down, ran away and threw it into a trash dumpster. The witness said the man then changed his mind, retrieved the turtle and put it into the back of a truck. The truck's license number was noted and police were called." 7/21/09 changed Species to CM.	No additional comments.
07/12/85	OAHU	Waikiki Beach	CM	U	40	-	0	Spear	Dead	Found speared in the head. Confiscated by the Honolulu Police Department from a man seen carrying it through Waikiki by zoo personnel. The turtle died in captivity several days later. Numerous newspaper articles, radio, and TV reports appeared about this case. NMFS-LE personnel also became involved.	No additional comments.
05/26/86 Turtle ID: 9101	HAWA	Kawaihae	CM	U	38.4	-	0	Spear	Alive	Found alive offshore in a weak condition with a spear hole in the carapace. Held in captivity at the Mauna Lani Bay Hotel and then shipped to NMFS in Honolulu. A fiberglass patch applied to wound by Dr. Patrick Leadbeater. Tagged and released off Niu Valley, Oahu on 10-2-86.	No additional comments.
05/27/86 Turtle ID: 8132	OAHU	Waianae	CM	F	-	-	-	Spear	Dead	Witnessed a turtle being speared in the head and killed by a person diving from a small boat.	No additional comments.
08/20/86	KAUA	Haena County Beach Park	CM	M	60	-	-	Spear	Dead	Found dead washed ashore in a fresh condition with spear holes in the right side of the carapace.	No additional comments.

70 of 6,584 (1.1%) Marine Turtle Strandings Due to Spear, Gunshot, Arrow, and Puncture-Related Trauma in the Hawaiian Islands, 1982 - July, 2013

DATE	ISLAND	LOCATION	SPECIES	SEX	SCL (cm)	CCL (cm)	TUMOR RANK	CAUSE OF STRANDING	END TURTLE STATUS	STRANDING DESCRIPTION	NECROPSY REPORT
09/13/86	OAHU	Kaneohe Bay	CM	U	68	-	0	Trauma	Dead	Found dead floating with an injury to L. side of head and jaw, possibly resulting from a powerhead.	No additional comments.
11/23/86	OAHU	Laie	CM	F	49.3	-	0	Gunshot	Dead	Found barely alive washed ashore with wounds on L. side of head, thought to be from shotgun pellets. Blood sample taken for parasite ova. Died the following day in captivity.	No additional comments.
03/05/87	OAHU	Maunaloa Bay (Portlock)	CM	U	54.2	-	0	Trauma	Dead	Found dead floating in advanced decomposition. Damage to carapace likely resulting from impact. Hole/wound in the gular region.	Stomach contained mainly 95% Acanthophora s. and Laurencia n.
03/28/87	OAHU	Kawela Bay	CM	U	-	-	-	Gunshot	Alive	Excessively buoyant and lethargic turtle seen floating close to shore on 3/28-29/87. Injuries described as "holes" in the flippers and side of the carapace. Suspected gun shot wounds.	No additional comments.
01/05/88	HAWA	Maunakea Beach	CM	U	-	-	-	Spear	Alive	Found alive but wounded. Returned to sea by person who speared it.	No additional comments.
04/20/89	HAWA	Hilo	CM	U	-	-	0	Spear	Dead	Found alive with an old and rusty spearhead in the carapace. Died on 4-26-89. Previously x-rayed and treated with Penicillin. Est. SL=50.8cm.	Necropsy performed by Hilo veterinarian Dr. Marta Lepes. Stomach contents- Pterocladia. Samples: stomach contents (Pterocladia) saved.
06/10/89	OAHU	Kahala/Waialae Beach	CM	U	-	-	0	Spear	Dead	Found dead washed ashore with a spear wound.	No additional comments.
06/18/89	OAHU	Sunset Beach	CM	U	44.5	47	0	Trauma	Dead	Found alive with small deep holes/punctures in neck. Given antibiotics and found dead at NMFS-KRF on 7-2-89.	Paravertebral sinus rupture? Samples: stomach contents, lung, liver, spleen, and kidney tissue saved. Stomach contents: 99% Gelidiella, 1% Amansia, and trace of Cermium, Codium, Microdictyon, Polysiphonia, and Sargassum.
08/28/89	HAWA	Wailoa River	CM	U	-	-	-	Arrow in neck	Alive	Found alive with an arrow in neck swimming. Est. SL=3'.	No additional comments.
08/28/89	OAHU	Kailua Bay	CM	F	43.5	46	-	FP/Trauma	Dead	Found dead with puncture in neck. Tumors on neck, RFF, tail, L./R. groin.	Covered with sand. Stomach and all through intestine full of Codium. Large puncture wound in dorsal neck. 3 parallel deep scratches in R. carapace.
09/12/89	HAWA	Reeds Bay	CM	F	-	81	0	Arrow in neck	Dead	Found dead and severely bloated. Arrow with a cord attached in its neck. Puncture wounds at approximately center top and center bottom of neck. Carcass photographed and then taken to dump. Est. weight=200 lbs.	No additional comments.
12/09/89	OAHU	Kawela Bay	CM	U	-	-	-	FP/Trauma	Alive	Found alive but reportedly tied to buoy and shot in the head. Tumors on L. flipper and eyes. Cut loose but very weak. Photo taken.	No additional comments.
02/07/90	OAHU	Waimanalo	CM	U	41.9	44.5	0	Spear	Dead	Found dead washed ashore.	Healed indentation 11mm. 1cm large puncture on 3rd R. lateral, likely spear hole. Right pectoral muscle has lesions. PC. Secretory stomach empty. Brownish sunburst shell. Samples: Codium and red leaf in crop saved. Crop contents: 65% Codium, 20% Pterocladia, 5% Amansia, 5% Lyngya, 3% Codium a., 2% Sargassum, and trace of Acanthophora, Microdictyon, Rosenvingia, and Valonia.
06/21/90	HAWA	Kahaluu Beach Park	CM	U	-	51	-	Spear	Dead	Gutted-out carapace with fine spear hole.	No additional comments.
08/05/90	MAUI	Maui Sun Condominiums	CM	M	47.8	51.5	1	Spear	Dead	Found alive with four puncture holes in head, likely spear wounds. Shipped to NFMS in Honolulu and taken to NMFS-KRF. Unable to swim straight. 5-16-91: motor skill and a recent bouyancy problems, especially when excited ie. spins uncontrollably. Appears blind in R. eye possibly optic nerve damage. Healthy appetite, very robust.	EU: on 4-3-92 for Dailey/Morris parasite study. One small nodule found in lung. Samples: humeri, stomach contents, and blood for Chemzyme analysis 510 and 520 saved.
10/25/90	KAUA	Hanamaulu Bay	CM	U	-	-	0	Gunshot	Dead	Found dead washed ashore. Cause of death by bullet wound in head. Photos taken.	No additional comments.
02/27/91 Turtle ID: Y737	OAHU	Sandy Beach Park	CM	U	-	-	0	Spear	Alive	Found alive speared. Photos taken and spear (15cm) removed from RFF. Tagged and released Kaneohe Bay, Mark's Reef on 2-28-91. Swam away favoring left flippers.	No additional comments.

70 of 6,584 (1.1%) Marine Turtle Strandings Due to Spear, Gunshot, Arrow, and Puncture-Related Trauma in the Hawaiian Islands, 1982 - July, 2013

DATE	ISLAND	LOCATION	SPECIES	SEX	SCL (cm)	CCL (cm)	TUMOR RANK	CAUSE OF STRANDING	END TURTLE STATUS	STRANDING DESCRIPTION	NECROPSY REPORT
06/09/91	OAHU	Found near Sea Life Park	CM	M	51	54	0	Spear	Dead	Found alive with a spear hole in its head, beak/nostril, and neck. Died later that day.	Fresh kill, 3 prong spear hole in head. Beak/nostril holes has 2cm tear through them, another hole noticed L. side of neck area. RFF claw chipped. CA and green algae material on plastron. SB. Intestine filled to capacity possibly Amansia, Codium, red filaments. Samples: stomach contents saved.
06/10/92	MAUI	Makena (Maui Prince Hotel)	CM	M	49.9	54	0	Spear	Dead	Found alive and injured. Survived two nights at the clinic and had improved. Shipped to NMFS in Honolulu via Hawaiian Air Cargo. 2-3 puncture wounds to the top of the head indicating spear wounds. A portion of its carapace had a deformity indicating an old injury.	CA. 4th central protruding deformity. Thick green fat. Crop 80% full, intestine 80% full. Stomach contents 95% of same food items. Samples: humeri, liver/lipid for W. Teas/NMFS, and stomach samples saved.
06/26/92	OAHU	Waianae ("Moi Hole")	CM	M	42.2	45	0	Spear	Dead	Found alive. Retrieved by Gene Witham (NMFS-LE).	CA. Mild emaciation. Rear marginals deformed (L. 9th-11th, R. 11th). Single puncture in center of head. Thick green fat. Stomach/intestine 70% full (stomach contents: 98% Amansia, 2% Codium). Samples: humeri, lipid/liver for W. Teas/NMFS, stomach contents and skull saved.
07/17/92	OAHU	Makaha Valley	CM	U	-	-	-	Spear	Alive	Found alive in a stream with possible 3-prong spear hole in head. Released outside of the Waianae Small Boat Harbor. Swam off strong. Photos taken. Est. SL=2', weight=35 lbs.	No additional comments.
02/15/93	HAWA	Kapoho Beach Lots	CM	U	-	-	-	Spear	Dead	Found dead washed ashore. Tumors present. Appeared to have been speared. Photos taken by D. Makaweo. Est. measurements: 26"L x 19"W. Not seen by NMFS.	No additional comments.
03/08/93	OAHU	Bellows AFB	CM	M	36.7	40	0	Trauma	Dead	Found dead washed ashore. Impact to head.	Fresh condition. CA on carapace. LFF missing, healed. Fecal pellet contained Codium. Dorsal R. side of head crushed area 3cm L x 1cm W, possible impact from intentional blow and adjacent puncture in skin. Stomach/intestine 75% full: 100% Codium edule. WNOI. Samples: humeri and LHF tracing.
08/23/95	HAWA	Mauna Kea Beach Hotel	CM	M	56.4	61.5	0	Spear	Dead	Witnessed being taken out of the water at the end of a spear. DOCARE confiscated turtle. Shipped to NMFS in Honolulu via TransAir on 5-2-97. Case# HA-96-066.	Necropsy performed by A. Aguirre. Mild decomposition. 8th/11th R. marginals healed notches. PPS. 3-prong spear wound, 4.5 x 4.5 x 4cm, on dorsal L. side of neck bordering head (area where skin and skull meet). Subcutaneous, spear causing hemorrhage to muscles on neck into the deep muscle, probably severed a nerve. Internal hemorrhage along esophagus/trachea, lots of clotted blood. Lungs full of fluid. 500ml bloody fluid in peritoneal cavity. G.I.T. 50% full. Cause of death: spear wound. Sample: forestomach contents: 90% Gelidiopsis i., 5% Amansia g., 3% Microdictyon, 1% Laurencia, 1% Ulva, and trace of Ceramium and Cladophora saved.
04/03/96 Turtle ID: H270	HAWA	Keawa Iki	CM	M	38.7	41	0	Spear	Dead	Found dead washed ashore. Retrieved by M. Rice and taken to HPA for storage. Brought back with GHB on 4-10-96 and taken to A2 freezer.	Advanced decomposition. Tail missing, possibly from decomposition. Possible spear hole on neck (ventral), 2cm diameter. Bi-valves growing in LFF, RFF, LHF, RHF tags. Very little fat. G.I.T. 40% full. PPS. Samples: humeri + tags, forestomach contents, intestinal contents, and stomach contents saved.
05/08/96	OAHU	Waikiki Canyons	CM	M	43.4	46	3	FP/Trauma	Dead	Found dead floating. Retrieved by Atlantis Submarines and taken to Pier 40.	Moderate decomposition. 1cm hole in 2nd L. lateral, possible spear. Two notches: 5th L. marginal (1.5cm long) and 6th L. marginal (2.5cm long). Crack in pectoral scute. PCA. Mild emaciation. G.I.T. 50% full. Very little fat. DB-5, VB-16. PPS. Samples: humeri and forestomach contents: 94% Hypnea m., 6% Codium a., and trace of Acanthophora s., Dictyota f., Gracilaria c., and Laurencia saved.
08/26/96	HAWA	Kaloko-Honokohau National Historic Park	CM	U	-	-	-	Spear	Dead	Found alive with 2 spear holes in its head and neck, not penetrating. Reportedly seen swimming in circles ~25 yards offshore on 8-28-96, but it was later found out to be dead.	No additional comments.
07/12/98	HAWA	Kawaihae	CM	F	58	61	0	Spear	Dead	Found dead washed ashore. Marc responded and met Richard there. Penetrating wound to upper portion R. side neck and below it, probable spear wound. Shipped to NMFS in Honolulu via TransAir on 7-21-98.	Necropsy performed by A. Aguirre. Moderate decomposition. CA. Perforation 0.5cm diameter R. dorsal neck, 1cm diameter perforating skin, muscle, L. ventral neck. Ventral wounds extending to trachea and invading adjacent muscle and forms abscess on both dorsal and ventral. Hemorrhage around trachea. A lot of foam in trachea (edema). Infection extends into coelomic cavity causing adhesions to intestinal loops. G.I.T. 60% full. Cause of death: septecemia caused by spear wound. PPS. Samples: humeri and forestomach contents: 100% Amansia g. and trace of Cladophora and Sphacelaria saved.

70 of 6,584 (1.1%) Marine Turtle Strandings Due to Spear, Gunshot, Arrow, and Puncture-Related Trauma in the Hawaiian Islands, 1982 - July, 2013

DATE	ISLAND	LOCATION	SPECIES	SEX	SCL (cm)	CCL (cm)	TUMOR RANK	CAUSE OF STRANDING	END TURTLE STATUS	STRANDING DESCRIPTION	NECROPSY REPORT
08/25/98	OAHU	Laie	CM	U	39.6	42.3	0	Spear	Dead	Found dead washed ashore in advanced decomposition. Possible spear hole on R./L. side on neck, 1cm. Photos taken. Tail missing due to decomposition. Carcass tagged and left for C & C Disposal. Also called in by Cassandra on 8-23-98.	No additional comments.
01/13/99 Turtle ID: 1F6D64711F	MAUI	Lahaina	CM	U	62.3	66	0	Trauma	Alive	Found alive 80 yards offshore, but later came slowly to shore. Seen bumping into reef. Retrieved by Skippy and taken to DLNR office. Puncture wounds to head. Shipped to NMFS in Honolulu via Aloha Air Cargo on 1-14-99. Transferred to Makai Animal Clinic for examination. Taken to NMFS-KRF on 1-15-99. Four puncture wounds to head: 2 on R. side near neck, 2cm; 1 L. side near neck, 2-3cm, part of skull protruding; and on L. side head, slightly bleeding. 8-10cm scratch on surface on 4th L. lateral. PPS. Digital photo and blood taken by GHB on 1-15-99. NMFS-KRF captive from 1/15-5/27/99. Tagged and released on 5-28-99 at Kawaikui Beach Park.	No additional comments.
05/31/99 Turtle ID: 4136022B63	OAHU	Kailua Bay (Kailua Beach)	CM	U	43.3	46	0	Spear	Alive	Found alive and beached. Contact took turtle to Sea Life Park. SSG tried to release turtle but it came back to shore. Photo taken. Taken to Makai Animal Clinic. Transferred to NMFS-KRF on 6-1-99. Three small puncture wounds on right side of head, ~.5cm diameter, possible spear wounds. PPS. Tagged and released on 11-3-99 at Kawaikui Beach Park.	No additional comments.
08/12/99	MAUI	Olowalu	CM	M	44.4	47	0	Spear	Dead	Found dead floating. Retrieved by contact and taken to Lahaina harbor. Picked up by Skippy and taken to DLNR office. Shipped to NMFS in Honolulu via Aloha Air Cargo on 8-13-99.	Cursory exam only. Three 0.5cm diameter indentations on L. prefrontals, possible three prong spear wound. Lots of body fat. G.I.T. 40% full. PCA. CA. PEP. PPS. Samples: humeri and forestomach contents: 56% Pterocladia c., 42% Amansia g., 2% Dictyosphaeria v., and trace of Microdictyon s. and Sphacelaria saved.
08/17/99	MAUI	Makena Landing	CM	F	70.3	75.5	0	Trauma	Dead	Found alive beached and lethargic. Skippy retrieved turtle on 8-18-99. Shipped to NMFS in Honolulu via Aloha Air Cargo. Taken to Makai Animal Clinic on 8-19-99. Transferred to NMFS-KRF on 8-20-99. Two puncture wounds on R. side of head behind eye. CA. Healed notch between 11th L. marginal and PC. Two 1cm diameter holes on L. abdominal and R. femoral. PPS. Given 3cc IM Amikacin on 8/23, 8/26, 9/10, 9/13, 9/15, 9/17, 9/20, 9/22, and 9/24/99.	EU/necropsy on 9-27-99 by Dr. T. Work. Case# 15243. Comprehensive report on file. Moderate emaciation. Left palstral scutes sloughing. Left and right head scutes sloughing. Samples: blood taken for plasma banking; humeri; forestomach contents: 100% Pterocladia c. and trace of Cladophoropsis and Derbesia; and tissues for banking: heart, lung, liver, kidney, and spleen saved.
02/27/00	LANA	Mauna Lei	CM	F	58.9	63	0	Gunshot	Dead	Found alive, beached and lethargic. Retrieved by contact and taken to his residence. Shipped to NMFS in Honolulu via Island Air on 2-28-00. Taken to Makai Animal Clinic. 0.5cm puncture wound to head. PPS. Blood taken for plasma banking. Transferred to NMFS-KRF on 2-29-00. Taken to Makai Animal Clinic on 3-1-00 for further observations. Examined by Dr. Morris on 3-4-00 and x-rays taken, showing BB in head.	EU/necropsy on 3-8-00 by Dr. T. Work. Case# 15291. Comprehensive report on file. Samples: blood taken for plasma banking; R./L. pectorals for Dr. Morris; R. Lu samples; steel BB; forestomach contents: 80% Acanthophora s., 12% Tubinaria o., 5% Laurencia, 3% Melanamansia g., and trace of Cladophora, Dictyosphaeria v., Hypnea c., and Lyngbya m.; and tissues for banking: heart, liver, kidney, spleen, and lung saved.
07/03/00 Turtle ID: 4136233742	OAHU	Wawamalu	CM	M	56.3	60.3	0	Trauma	Dead	Found dead washed ashore. Contact bagged carcass and left under bridge. Existing mototool #5 and line on 1st central, white paint. Two puncture wounds in back of neck near carapace. PPS.	Necropsy on 7-26-00 by Dr. T. Work. Case# 15357. Comprehensive report on file. Two small puncture wounds, <.5cm diameter, in dorsal neck associated with extensive bleeding in adjoining musculature. Dorsal photo taken by GHB. Forestomach sample has a pasty mass (from stomach) added to sample. Samples: HF for PIT, humeri, and forestomach contents saved.

70 of 6,584 (1.1%) Marine Turtle Strandings Due to Spear, Gunshot, Arrow, and Puncture-Related Trauma in the Hawaiian Islands, 1982 - July, 2013

DATE	ISLAND	LOCATION	SPECIES	SEX	SCL (cm)	CCL (cm)	TUMOR RANK	CAUSE OF STRANDING	END TURTLE STATUS	STRANDING DESCRIPTION	NECROPSY REPORT
11/30/00 Turtle ID: Q419	HAWAII	Puako	CM	M	43.2	45.5	0	Spear	Dead	Found barely alive. Shipped to NMFS in Honolulu via Aloha Air Cargo. Taken to Makai Animal Clinic where it later died. Transferred to NMFS lab on 12-1-00.	Necropsy performed on 12-1-00 by GHB. Examined by T. Work on 12-11-00. Case# 15397. Comprehensive report on file. Thick algal mat on carapace. Separation of skin and anterior edge of carapace over a 12cm area (likely autolytic separation). Very soft plastron. Severe emaciation. PPS. Left side posterior skull 4cm impact injury through bone. Left anterior plastron small puncture extending to pectoral muscle, likely 3-prong spear. Pectoral muscle severely atrophied. Three "bumps" on soft palate. Lungs inflated, green (infected). Spleen has 2 black nodules on covering membrane. Gonads-testes are mainly white. No body fat. Esophagus and crop has fresh algae (red filaments, Codium, Turbinaria). Algae in stomach and upper intestines densely packed. Several WNOI. Plastron, tag, and food photos taken. Samples: forestomach contents and tissues for histo: soft palate, glottis with gular bone, heart, liver, spleen, lungs, testes, bladder, kidney, upper intestines, stomach, brain, salt glands, PIT tag in muscle saved for T. Spraker.
09/14/01	OAHU	Kahana Bay Beach Park	CM	U	51.5	56	0	Trauma	Dead	Found alive swimming in circles for hours. Contact brought turtle to shore. Taken to Makai Animal Clinic. Two small puncture wounds in head. Right eye bulges out a lot. LFF limited movement. Blood taken by Dr. Morris. PPS. Transferred to NMFS-KRF on 9-17-01. Given 0.8cc (40mg) IM Amikacin on 9/20 and 9/23/01. Examined by Dr. Morris on 10/3. Examined and force-fed squid by Dr. Morris/GHB on 10/12. Examined by Dr. Morris/GHB on 10/26. Given 100mg IM Baytril on 10/30, 11/2, and 11/5. Given 3 antibiotic tablets on 12/8-12/14. Given 0.75cc IM Amikacin on 12/10, 12/14, 12/17, 12/20, and 12/22. Taken to Makai Animal Clinic for EU by Dr. Morris on 1-7-02. FedExed to Dr. T. Spraker for comprehensive necropsy, histology, and virology.	No additional comments.
09/22/01	OAHU	Kaneohe Bay (Kahaluu)	CM	U	64.1	69.5	1	Spear	Dead	Found dead floating near contact's boat dock. Retrieved by contact and taken to his residence.	External exam only on 9-24-01. PPS. VB-1. Two small holes L. side of head, one small hole in pre-central, and one small hole in 2nd L. lateral, possible spear wounds,.5cm and 1cm diameter.
03/28/02	MAUI	Makena (Little Beach)	CM	U	60.4	65	0	Spear	Dead	Found dead (thought to be alive) floating upside-down. Contact brought turtle to shore. Quarter-size hole in LHF. Shipped to NMFS in Honolulu via Aloha Air Cargo.	Necropsy performed on 4-23-02. No PPS. Axial: 25.0cm, lateral: 25.2cm. 8cm cut on base of LHF. Severed intestines hanging out, most likely due to spear puncture. Sand and food material in body cavity. Thick green fat. G.I.T. filled to capacity. Amansia in forestomach sample. Samples: two dense SB patches with skin in alcohol saved for Dr. Zardus and skin in salt packet for DNA saved.
04/11/02	OAHU	Electric Beach	CM	M	54.5	57.5	0	Gunshot	Dead	Found dead in shallow water. Retrieved by contact and taken to friend's house in Lanikai. Spear wound to head and right rear carapace. NMFS-LE notified.	Necropsy performed on 4-23-02. 1cm diameter hole between 3rd-4th L. lateral. Possible bullet or spear wound (most likely bullet) extending through body cavity and exiting out of plastron through the L. femoral scute. PCA. 3.5cm x 1cm indentation between 2nd central-2nd L. lateral. No PPS. Axial: 24.2cm, lateral: 24.3cm. Intestines clearly pierced at several places. G.I.T. 80% full. Samples: forestomach contents and skin in salt packet for DNA saved.
09/15/02	OAHU	Waimanalo	CM	M	66.5	70.5	0	Trauma	Dead	Found dead washed ashore. Right side of neck has 1cm diameter puncture wound.	Necropsy performed on 9-20-02. Moderate decomposition. Puncture wound does not protrude through neck muscle. CA on carapace and plastron. 1st central and posterior end of 2nd central humped, skewing axial measurement. Gaseous and bloated. PPS. Axial: 28.5cm, lateral: 29.3cm. Samples: humeri, forestomach contents, and skin in salt packet for DNA saved.
08/08/03	MAUI	Lahaina Jodo Mission	CM	F	72.6	79	0	Spear	Dead	Found dead washed ashore with rope tied around its neck. End of rope was attached to a small spear (kui) that was stuck in the sand. Holes in top and side of head. Taken to MCC-MOP freezer. Shipped to NMFS in Honolulu via Aloha Air Cargo on 10-6-03. Taken to Halawa on 10-7-03.	Necropsy performed on 11-7-03 by Dr. T. Work. Case# 17761. Comprehensive report on file. Axial: 29.3cm, lateral: 30.6cm. Left side of head has 2 holes, 2cm deep, below eye. Small hole on L. lateral dorsal head. Lots of body fat. Excellent body condition. PPS. Samples: humeri, forestomach contents, and skin in salt packet for DNA saved.
10/07/03	OAHU	Waianae (Hawaiian Electric Beach)	CM	U	43.1	46.5	0	Spear	Dead	Found dead floating. Retrieved by dolphin tour group and brought to Waianae Boat Harbor. Placed in Waianae Ice House freezer. Three small holes in top of head, indicative of 3-prong spear. No PPS. VB-1. Axial: 16.9cm, lateral: 16.7cm.	Necropsy performed on 11-19-03. Mild decomposition. Puncture wounds on head: 3, 3.5, and 3.5cm apart. Depth of punctures: 3, 1.25, and 1.5cm. Good body fat. G.I.T. 15% full, forestomach 10% full. Samples: forestomach contents, skin in salt packet for DNA, and photos of head trauma saved.

70 of 6,584 (1.1%) Marine Turtle Strandings Due to Spear, Gunshot, Arrow, and Puncture-Related Trauma in the Hawaiian Islands, 1982 - July, 2013

DATE	ISLAND	LOCATION	SPECIES	SEX	SCL (cm)	CCL (cm)	TUMOR RANK	CAUSE OF STRANDING	END TURTLE STATUS	STRANDING DESCRIPTION	NECROPSY REPORT
10/11/03	HAWA	Kaloko-Honokohau National Historic Park	CM	M	49.5	52	0	Trauma	Dead	Found barely alive. When Sallie checked on turtle before shipping it had died. Deep puncture-like wound on neck, 1cm wide. Carcass taken to Kaloko-Honokohau freezer. Shipped to NMFS in Honolulu via Aloha Air Cargo on 9-14-04. Taken to Halawa on 9-29-04. SB. Right side of neck has 2cm deep x 2cm diameter hole (area swollen) that doesn't penetrate neck muscle. 2cm long x 0.5cm deep gash in gular scute, doesn't penetrate bone. Mild emaciation. No PPS. Axial: 15.7cm, lateral: 16.0cm.	Necropsy performed on 10-6-04. Mild decomposition. ~300ml bloody fluid in body cavity. 39cm of small intestines has H2S (black). Pectoral muscles very red. 1cm black nodule on aorta wall. Tissues around neck very dark purple and swollen. Very little body fat. G.I.T. 20% full. Samples: humeri, forestomach contents, rest of forestomach contents frozen, skin in salt packet for DNA, and digital photos taken.
03/09/08 Turtle ID: 4607661036	OAHU	Kailua Bay (Kailua Beach Boat Ramp)	CM	U	40.1	43	0	Spear	Alive	Found alive in a dive bag stuck under a rocky ledge. Diver brought bag to shore and gave it to DOCARE. Turtle was very lethargic, unable to swim, and was bleeding from the head/neck area. Taken to Makai Animal Clinic. Puncture wound anterior to the brain and the R. side of the neck, probably 3-prong spear. Wounds were cleaned. Given 1cc Amikacin. Transferred to NMFS-KRF on 3-11-08. CA on plastron and carapace. No PPS. Crusty sand-like bright green grains around tail and ventral cloaca. Old healed cracks through 11th L./R. laterals. Mototool 6D on 2nd L./R. laterals. Tagged and released on 4/29/08 at Kawainui Canal.	No additional comments.
06/20/08	OAHU	Maili (Nanikai Beach Park)	CM	F	48.2	53	1	Spear	Dead	Found reportedly alive and seen lifting its head to occasionally breathe. NMFS was contacted hours later and by the time NMFS picked up the turtle it was dead. (Possibly turtle was already dead as there were sloughing of a RFF scale.)	Two punctures in the neck, possibly spear or fish hook? Very bloody internally at punctures due to the veins being hit. Pale muscles. Ovaries deep red. Samples: forestomach contents, skin in saline solution for DNA, and digital photos.
03/06/09	OAHU	Waimanalo Beach Park	CM	M	49	52	0	Spear	Dead	Found alive rolling in the whitewash. Tourists put turtle back in to water, but it was unable to dive or swim. Contact retrieved turtle and brought above high tide line. Picked up by NMFS and taken to Makai Animal Clinic. Trauma to R. eye, no vision. Two puncture wounds to head, old and healed. Turtle unable to move flippers well. Overall not much reaction. Examined then EU by Dr. Morris. Blood taken by Dr. Morris.	Spear puncture wounds on skull, but not causing death. Right distal puncture wound is very deep, went into right eye salt gland affecting the eye. Eye trauma not recent. Lots of muscles pink. Multiple WNOI in first meter of intestines. Lungs collapsed. Significant amount of sand in esophagus.
03/16/09	MOLO	Hono Uli Wai	CM	U	-	-	0	Spear	Alive	Found alive turtle beached on the rocks. Puncture wounds on plastron due to possible spear. Contact pushed turtle back into water, but it returned to the rocks. DOCARE-Molokai was notified. Bill herded the turtle into a fishpond. Turtle seemed lethargic. Puncture wounds appeared deep and old, no bleeding. Bill called contact on 3-17-09 and turtle had swam away. Contact reported that the turtle appeared buoyant but far offshore.	No additional comments.
06/04/10	OAHU	Ala Wai Yacht Harbor	CM	F	71.2	76	1	Spear	Dead	Report of a dead turtle buried on the beach. Unknown location, therefore not responded to by NMFS. Contact called back on 6-5-10 and the location was found. SSG responded and retrieved the carcass and brought back to NMFS' freezer.	Lots of bloody fluid in body cavity. Atrophied pectoral muscles. Serous body fat. Small pieces of fishing line found in large intestines. Left upper jaw has Kevlar line looped, 10cm, rubbing and eroding directly below. Rubbing formed "pie-shaped" tissue which the line hooked on to. Three punctures through skull and one through anterior section of brain. 15 lb monofilament fishing line and wad of Kevlar found in intestines causing intussusception.
06/13/10	OAHU	Bellows Beach Park	CM	M	48.2	51.5	0	Trauma	Dead	Found alive with a puncture wound on the head. Turtle was retrieved by beachgoer and put into a small pool. Picked up by SSG and taken to NMFS.	Sand in brain cavity. Penetration trauma to top of brain case.
07/14/10	OAHU	Lanikai	CM	F	55.4	63.5	0	Spear	Dead	Found dead floating in the water. Contact brought carcass to shore. Picked by NMFS and taken to NMFS' freezer. Several puncture wounds on dorsal side of the head.	Three puncture wounds on head penetrating bone, possible three-prong spear strike. One puncture wound posterior of right eye. Enlarging ovaries.

70 of 6,584 (1.1%) Marine Turtle Strandings Due to Spear, Gunshot, Arrow, and Puncture-Related Trauma in the Hawaiian Islands, 1982 - July, 2013

DATE	ISLAND	LOCATION	SPECIES	SEX	SCL (cm)	CCL (cm)	TUMOR RANK	CAUSE OF STRANDING	END TURTLE STATUS	STRANDING DESCRIPTION	NECROPSY REPORT
07/16/10	OAHU	Kaiona Beach Park	CM	F	50.9	54.5	0	Spear	Dead	Found dead after being poached with a spear gun. Four puncture wounds in the top of the head. DOCARE responded to the case and brought the turtle to NMFS on 7/17/10.	Brain case punctured. Four identical puncture wounds on the dorsal head that did not penetrate brain cavity. Severe diffuse bleeding in the neck musculature.
09/07/10	HAWA	Keauhou Harbor	CM	M	52.7	56	0	Trauma	Dead	Found dead floating upside down about 3 miles off of the harbor next to large, clean net. Retrieved by contact and brought to shore. Contact then brought carcass to HIHWNMS-Kona at Honokohau. Shipped to NMFS in Honolulu via Aloha Air Cargo on 7-28-11. Transferred to NMFS on 7-29-11.	Hemorrhaged muscle/trauma in underlying neck muscle from a puncture wound.
11/19/11	OAHU	Aina Haina	CM	F	-	-	0	Trauma	Dead	Found alive floundering at water surface. Contact and a friend retrieved the turtle and brought it to shore. SSG picked up and took it to NMFS. Two deep puncture holes in central head scute bleeding. Taken to Makai Animal Clinic on 11-20-11 by SSG. While being transferred to NMFS on 11-21-11 turtle had died.	Necropsy training session for HPU students. Multiple punctures on the dorsal cranium and neck with severe bleeding in the brain case. Clotted blood in the coelomic cavity.
11/25/11	KAUA	Kukuiula Boat Harbor	CM	M	46.4	50	0	Trauma	Dead	Found dead. No other information given. Contact noted that it may have drowned in gillnet, but unlikely.	1cm healed notch in 12th L. marginal. 1 puncture wound on dorsal L. neck, 1 x 1cm. Hemorrhaging in left pectoral muscle. Fracture to corticoid process ("trail" from neck entry through pectoral muscle). Despite extensive search for bullet none was found.
04/11/12	OAHU	Waimanalo Beach Park	CM	F	41.7	44	0	Trauma	Dead	Found dead washed ashore with a spear wound on its head. Turtle was given to DLNR by lifeguards who had buried it near their lifeguard station hours earlier. Two puncture holes made by a spear prong in dorsal head, ~0.5" diameter. Slightly bloated plastron. DOCARE case opened.	2 puncture wounds to the head, 0.5cm diameter. Plastron slightly bloated from exposure on the beach. Some small plastic pieces ingested and found in the crop. Comments from Dr. T. Work: Traumatic penetration of the calvarium. Maceration of the brain. The left salt gland macerated as well. Sand penetrating the structure via the wound hole.

70 of 6,584 (1.1%) Marine Turtle Strandings Due to Spear, Gunshot, Arrow, and Puncture-Related Trauma in the Hawaiian Islands, 1982 - July, 2013

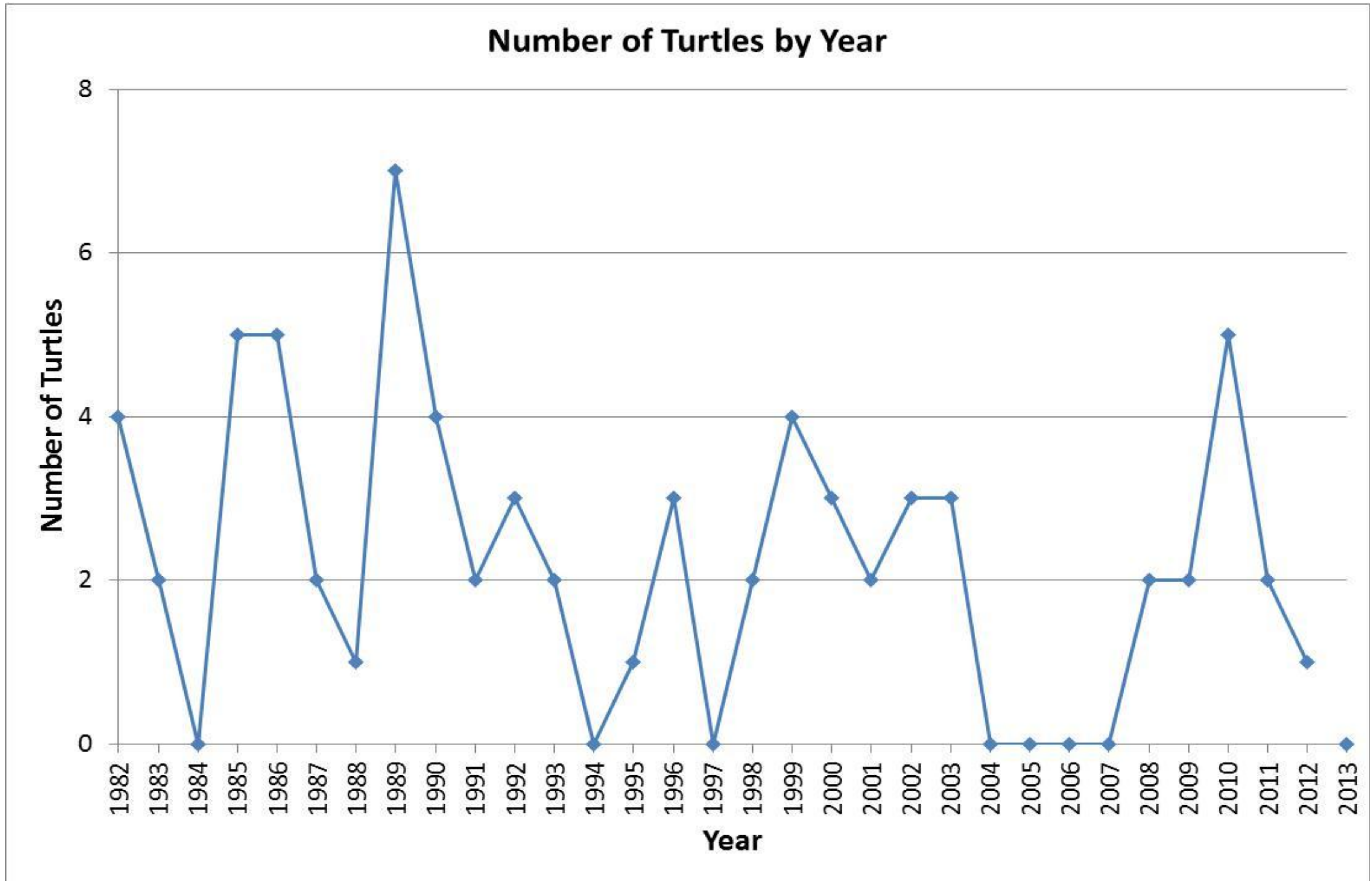


Figure 1. Number of marine turtle strandings due to spear, gunshot, arrow, and puncture-related trauma in the Hawaiian Islands by year, 1982 - July 2013.

70 of 6,584 (1.1%) Marine Turtle Strandings Due to Spear, Gunshot, Arrow, and Puncture-Related Trauma in the Hawaiian Islands, 1982 - July, 2013

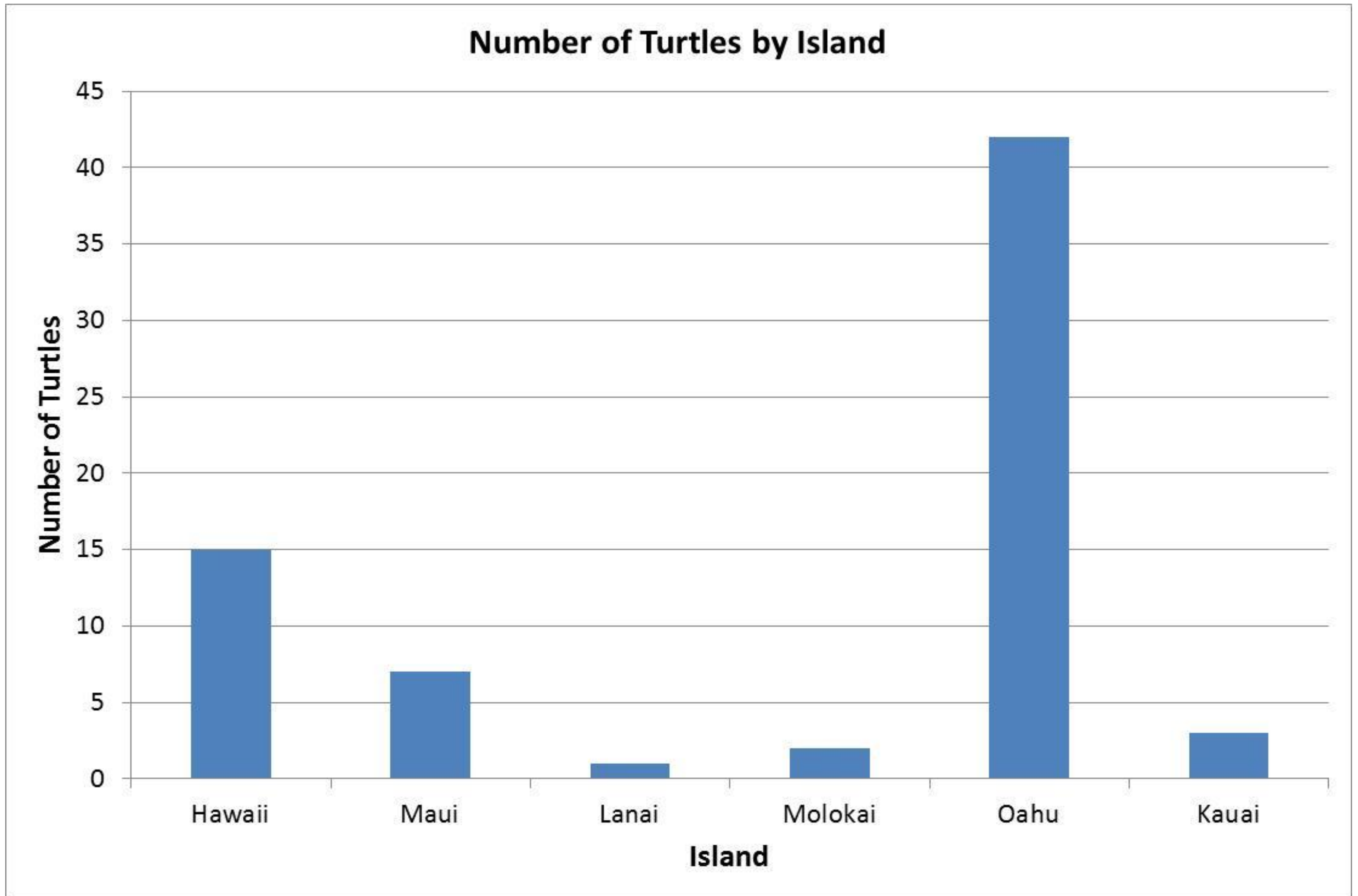


Figure 2. Number of marine turtle strandings due to spear, gunshot, arrow, and puncture-related trauma in the Hawaiian Islands by island, 1982 - July 2013.

70 of 6,584 (1.1%) Marine Turtle Strandings Due to Spear, Gunshot, Arrow, and Puncture-Related Trauma in the Hawaiian Islands, 1982 - July, 2013

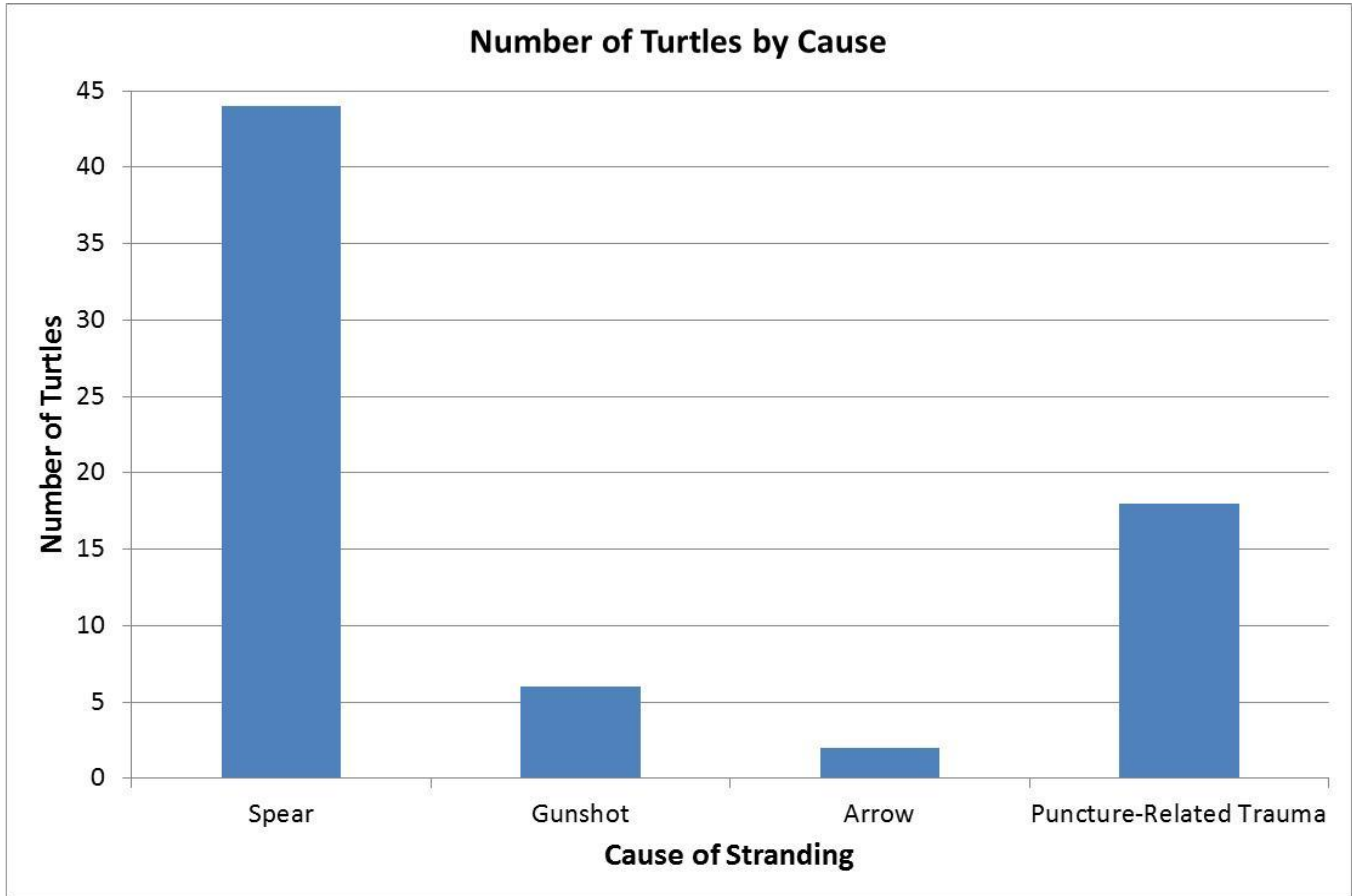


Figure 3. Number of marine turtle strandings due to spear, gunshot, arrow, and puncture-related trauma in the Hawaiian Islands by cause, 1982 - July 2013.

70 of 6,584 (1.1%) Marine Turtle Strandings Due to Spear, Gunshot, Arrow, and Puncture-Related Trauma in the Hawaiian Islands, 1982 - July, 2013

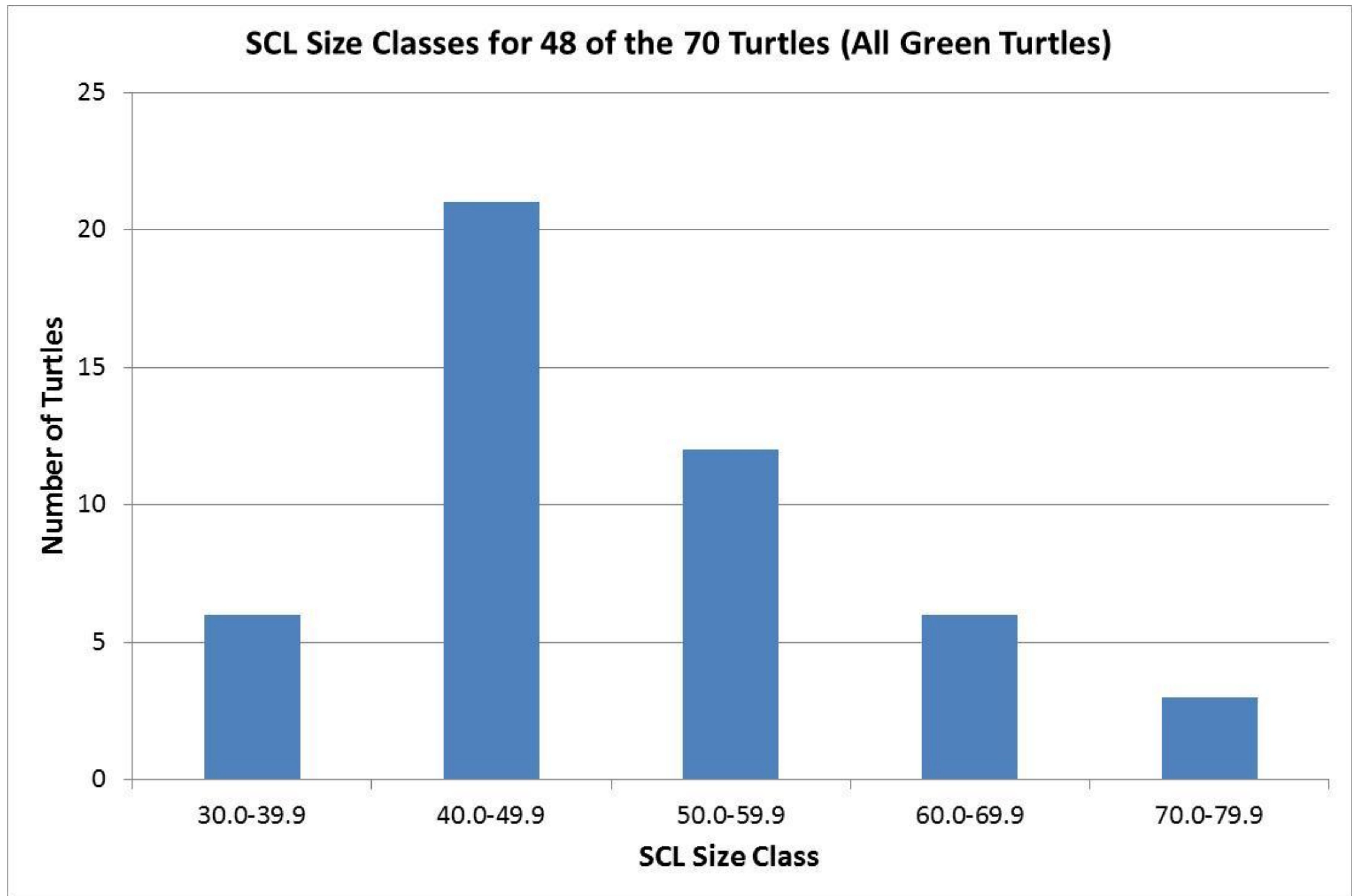


Figure 4. Number of marine turtle strandings due to spear, gunshot, arrow, and puncture-related trauma in the Hawaiian Islands by SCL Size Class, 1982 - July 2013.