

1-17-85 ~~KURE MORTALITY~~ Dissection at  
THURS. NMFS "A-2" with Robert Forsythe

S - 39.9 cm X 33.7 cm  
Notch 39.6 cm

C - 42.0 cm X 38.4 cm

PL - 31.5 cm

HEAD - 6.5 cm

TAIL - 7 cm

3-4 photos w/ flash.

found late  
~~Sept 11/1/84~~  
11/1/84

PHOTOS

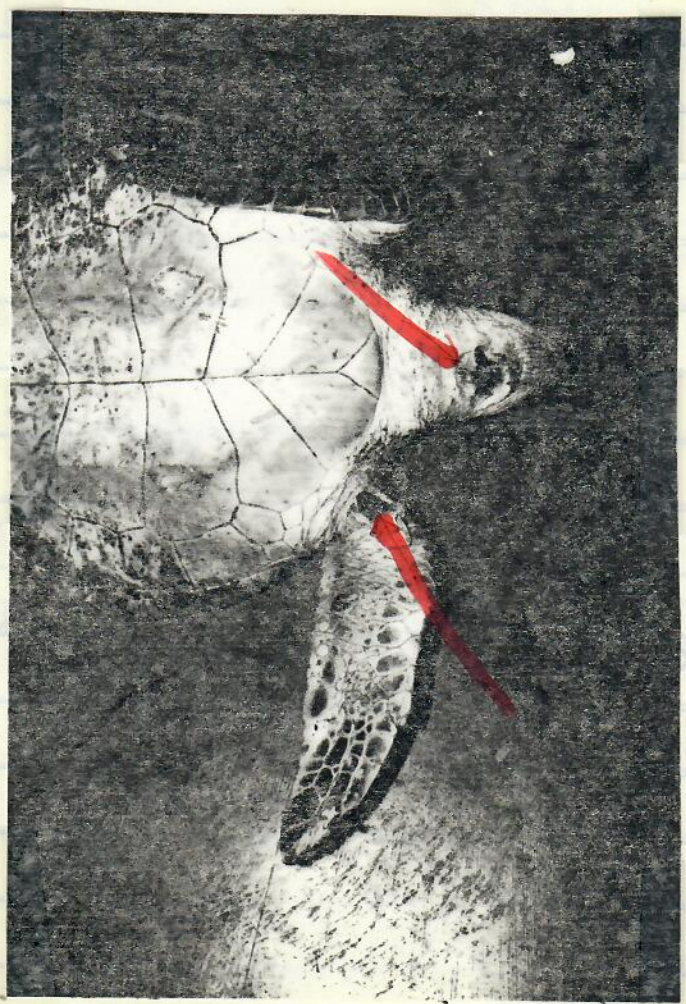
Reasonably fresh, but large hole in ventral throat with tissue damaged skin surrounding it. Hole revealed severed esophagus and trachea (right at Glottis). Hole also in ventral shoulder area of left front flipper. Section of skin seems to have a clean slit. Spear wound? or some unknown predator? or Freak accident.

All seemed normal internally. Right lobe of liver sampled to use for plasticizer analysis (Bayan). Stomach



1-17-85

Thurs. and intestines have moderate fill. of food - Stomach had Codium and Laurencia(??) small pieces. Codium throughout intestines, but 2 pieces of Turbinaria(?) found. Sample retained. Oviducts located running to cloaca to anterior lungs. 2 humeri saved.



6cm