

DIAGNOSTIC CASE REPORT

U. S. GEOLOGICAL SURVEY-BIOLOGICAL RESOURCES DIVISION
NATIONAL WILDLIFE HEALTH CENTER-HONOLULU FIELD STATION
P. O. BOX 50167, 300 ALA MOANA BLVD., Rm. 8-132
HONOLULU, HAWAII 96850
Tel: 808-792-9520, Fax: 792-9596, Email: thierry_work@usgs.gov

Case Number: 25222

Submitter Name:

Dr. Thierry Work
US Geological Survey
PO Box 50187
Honolulu, Hawaii 96850
United States

Species submitted (n):

Turtle: Green (1)

| | | | |
|-----------|---------------|----------------|-----------|
| Location: | Tunnels | DateCollected: | 7/14/2015 |
| Area: | Kauai | DateSubmitted: | 7/14/2015 |
| State: | Hawaii | DateReceived: | 7/14/2015 |
| Country: | United States | DateExamined: | 7/14/2015 |

SPECIMENS SUBMITTED: Skin lesion-Fixed formalin

History: Turtles with flipper lesions of varying severity have been intermittently spotted by Mr. Terry Lilley at Tunnels Beach on N. Kauai (Fig. 1). This prompted a joint field investigation on 14-15 July, 2015 between USGS, NOAA, Hawaii DLNR, and Terry Lilley the objectives of which were to 1) Determine the extent of the problem at Tunnels and 2) Attempt to capture any turtles with flipper lesions to obtain biopsies and rule out possibility that infectious agents might be involved with flipper lesions.

Findings: We (Terry Lilley, Scott Bacon, Don Heacock, George Balazs, Thierry Work, Renee Breeden) carried out 2 days of snorkel surveys at Tunnels in three locations (Currents, Cleaning station, and Tunnels) (Fig. 2). Several (ca. 30) juvenile turtles were seen at Tunnels grazing *Pterocladia* growing in crevasses and holes in the substrate. Occasional clumps of *Turbinaria* were also present but were not seen to be grazed upon by turtles. Turtles were unafraid of divers, behaved normally, and were in good body condition with no evident gross lesions except for a single animal in fair body condition with overgrowth of algae on caudal carapace. A much smaller number (2) of turtles was seen at the cleaning station, and only on Day 2; all of these were larger turtles in good body condition with no gross lesions. At the currents area, water was moving rapidly nearshore, and larger turtles in good body condition with no lesions were seen hovering over sand eating algae (*Microdictyon*) that was carried towards them by currents. Examination of fish in all locations revealed no abnormalities other than black discoloration in spotted puffer *Canthigaster jactator*.

A single green turtle was captured for examination on Day 1 (the small turtle in fair body condition). This animal had a small ulcer on the ventral portion of the left rear flipper (Fig 3) that was biopsied. Laboratory results of this biopsy revealed mild ulceration with no evidence of infectious agents, and blood work on this animal was unremarkable. The animal was released and has since be resighted and behaving normally by Terry Lilley.

Final diagnosis: Accession 1-Dermatitis.

Comments: All turtles appeared essentially unremarkable, and the one animal sampled had no evidence of infectious disease. This still leaves open the question of what caused the lesions seen in the front flippers of the turtles seen previously (Fig. 1). Whatever is affecting the flippers of these particular turtles appears to be limited to *C. mydas*, because we did not see lesions in the appendages (fins) of numerous other fish in the area. The problem also does not appear to be widespread in green turtles in the area. Given the normal behavior and good body condition of turtles in the area, it also does not appear that there is an underlying

physiologic problem.


Rather, the selective nature of these lesions (affecting only *C. mydas*) and their appearance (Fig. 1) suggests them to be traumatic in nature, perhaps induced by crabs, fish, turtles, or monk seals. It is unlikely that crabs could cause this kind of trauma in this size class of turtles. I am not aware of cleaner fish inducing this level of trauma in turtles, and if this were even the case, it would be hard to explain the limitation of lesions to front flippers. Sharks can cause trauma to turtle flippers, but this is in the form of traumatic amputation of entire limbs and not manifested by the lesions seen in Figure 1. I have seen rear flipper and tail trauma induced by turtles biting each other in highly crowded conditions in captivity, but this situation does not apply at Tunnels; turtles there did not appear overcrowded. This leaves monk seals as a the final and likely suspect. The ventral/dorsal distribution of the lesions at the caudal margins of flippers would be compatible with bite trauma from large mammal. We did note signs on the beach indicating that monk seals do haul out on beaches at Tunnels, so this has to be entertained as a possibility. There are certainly several documentations available in the public domain of Hawaiian monk seals and green turtles interacting.

Management: Confirming that monk seals are responsible for flipper trauma in turtles would require actual documentation of monk seal biting front flippers and causing lesions similar to those seen in Fig. 1. Determining how to do that will prove challenging.

Report Date (mm/dd/yyyy): 8/11/2015

Necropsy report: Enclosed

Copies of this report sent to:



If you have questions regarding this case, contact Thierry M. Work MS, DVM, MPVM at 808-792-9520. Include above Case Number. Diagnostic findings may not be used for publication without the pathologist's knowledge and consent.

NOTE: Information in this report supersedes any information from previous reports regarding this case



Figure 1. Representative clips of videos from Terry Lilley at various dates showing varying degrees of active and healed flipper lesions in green turtles from Tunnels. Captions on photos from Terry Lilley. Dates inserted by TM Work

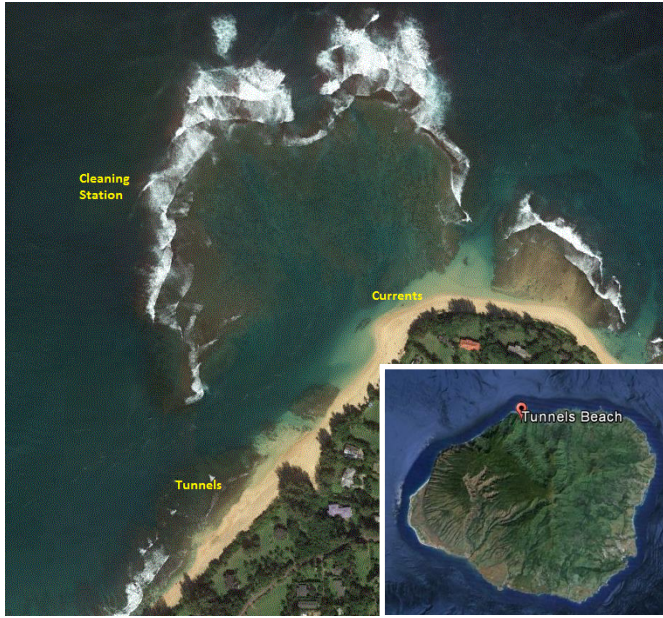

Figure 2. Locations surveyed at Tunnels on 14-15 July, 2015 with inset of location on Kauai.




Figure 3. A-B) Dorsal and ventral shot of turtle biopsied, c) Lesion biopsied, D) Photo of same turtle at Tunnels taken by Terry Lilley 6/14/2015. Caption on photo from Terry Lilley, dates inserted by T. Work.